

CASE Report

Oleo-keratin granulomatosis of the peritoneum: A rare case

Shikha Dhawan, Ranjana Gupta, Kumari Aparajeeta, Shivika Gupta, Kanchan Dalmia

Department of Obstetrics and Gynecology, Rohilkhand Medical College and Research Centre, Bareilly, Uttar Pradesh, India

Corresponding Author:

Dr. Ranjana Gupta, Department of Obstetrics and Gynecology, Rohilkhand Medical College and Hospital, Bareilly, Uttar Pradesh, India. E-mail: ranj2036@gmail.com

Received: 16-03-2019

Accepted: 28-03-2019

How to cite this article:

Dhawan S, Gupta R, Aparajeeta K, Gupta S, Dalmia K. Oleo-keratin granulomatosis of the peritoneum: A rare case. *Int J Adv Integ Med Sci* 2019;4(1):25-27.

Source of Support: Nil,

Conflicts of Interest: None declared.

Introduction: Chronic giant cell granulomata represent the typical response of the body to a varied range of noxious or irritant agents acting at a low level of toxicity. Surprising that two substances made by the organism itself, keratin and sebum, are among the most potent granuloma producers. Oleo-keratin granulomatosis of the peritoneum represents the typical response of the body (peritoneum) to the sebum. **Case Study:** A young nulliparous female with complaints of abdominal distention and fever. On examination, the patient was conscious, well oriented with stable vitals. Mild pallor was present. On P/A, there was distention with a suprapubic bulge of 12 × 10 cm in the lower abdomen extending up to the umbilicus. The mass had restricted mobility, non-tender, variegated in consistency, with ill-defined margins. On P/S examination, thick mucoid discharge was present. P/V examination showed normal size retroverted uterus. On p/R examination, rectal mucosa was free. **Conclusion:** Dermoid cyst is the most common benign tumor of the ovary, occurring in the reproductive age group. The malignant change in this benign tumor is very rare (approx. 1%) and the usual malignancy is squamous cell carcinoma and sarcoma if at all. The clinical picture of leaked/ruptured dermoid cyst produces a clinical picture of malignancy. The prognosis of this condition is otherwise quiet good, but the presentation is unique and occurrence quite rare.

KEY WORDS: Adhesions, oleo-keratin granulomatosis, ovary, peritoneum

INTRODUCTION


Chronic giant cell granulomata represent the typical response of the body to a varied range of noxious or irritant agents acting at a low level of toxicity.^[1] Among the very long list that could be made of such agents, it is somewhat surprising that two substances made by the organism itself, keratin and sebum, are among the most potent granuloma producers. Rarely, but then often disastrously, keratin and sebum gain access to the peritoneum. The source is always dermoid cyst of the ovary which has suffered some form of damage, either infarction or rupture.^[1]

They may be responsible for complications such as torsion, rupture, and obstruction during labor. Rupture is rare, but once it has occurred, it can cause complications such as chemical or granulomatous peritonitis mimicking advanced ovarian malignancy.^[2-4]

Oleo-keratin granulomatosis of the peritoneum represents the typical response of the body (peritoneum) to the sebum. The sebaceous contents from the dermoid cyst of the ovary leak into the general peritoneal cavity and with the passage of time, this process leads to the formation of adhesions in the abdomen involving the intestine, omentum, ovaries, and fallopian tubes. Later on, the peritoneal reaction leads to the development of ascites as well. This clinical picture is confused with malignancy of the ovaries. Very few cases have been reported in the medical literature. Because of rarity of the condition, the present case is reported.

CASE HISTORY

A 23-year-old female, nullipara, came to our hospital with the complaints of vague mass abdomen since the past 2 years,

Access this article online	
Website: www.ijajims.net	Quick Response code
	

This is an Open Access article distributed under the terms of the Creative Commons Attribution 4.0 International License (<http://creativecommons.org/licenses/by/4.0/>), allowing third parties to copy and redistribute the material in any medium or format and to remix, transform, and build upon the material for any purpose, even commercially, provided the original work is properly cited and states its license.

distention of the abdomen for the past 10–15 days, and low grade fever for 5 days. Her last menstrual period was on 16 September, 2015 (7 days back), bleeds for 3 days with a cycle length of 28 days, regular, normal flow, mild dysmenorrhea. She was married for the past 5 years and the couple was not using any contraception.

On examination, the patient was conscious, well oriented with stable vitals. Mild pallor was present.

On abdominal examination, there was distention with a suprapubic bulge of 12×10 cm in the lower abdomen extending up to the umbilicus. The mass had restricted mobility, non-tender, variegated in consistency, with ill-defined margins. On per speculum examination, thick mucoid discharge was present.

P/V examination showed normal size retroverted uterus.

On per rectal examination, rectal mucosa was free.

Investigations revealed that Hb was 11.1 gm%, a TLC of $5600/\text{mm}^3$, platelet count of $2 \text{ lac}/\text{mm}^3$, and a raised CA 125 level of 12,551.80 u/ml.

Ultrasonography suggested right-sided dermoid cyst of 10×12 cm with evidence of ascites. CT abdomen showed multiseptated thick-walled heterogeneous lesion having fatty and cystic components.

The patient was posted for exploratory laparotomy followed by removal of the dermoid cyst and the sebaceous material from the abdomen, adhesiolysis, and a saline wash of the abdominal cavity.

Intraoperative Findings

- Ascites approx. 1800–1900 cc.
- A large cyst mass approx. 20×18 cm seen arising from the pelvis
- Adhesions all around, mobility is restricted
- Multiloculated left-sided ovarian cyst
- Multiple granulomatous lesions on omentum, bowel, peritoneum, and under surface of the liver arising as a result of sebaceous material leakage [Figures 1 and 2].
- On right side fallopian tube (distal part with fimbrial end).
- On left side no tube and ovary seen. Uterus was normal in size.

On gross examination, a large cystic mass of 12×10 cm with smooth surface adherent to intestines was seen and cut section revealed, sebaceous material from the cyst, tuft of hair with multiple teeth [Figure 3].

Microscopy

Histopathology of the lesion confirmed benign cystic teratoma of the ovary with chronic non-specific inflammatory pathology. Ascitic fluid was negative for malignant cells.

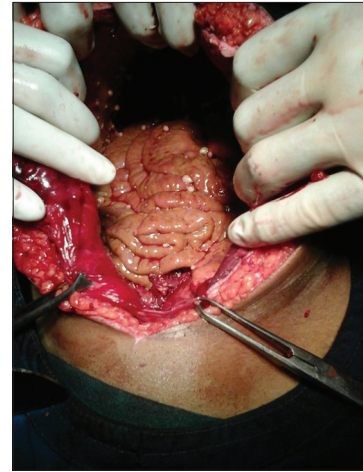

Figure 1: Ascitic fluid

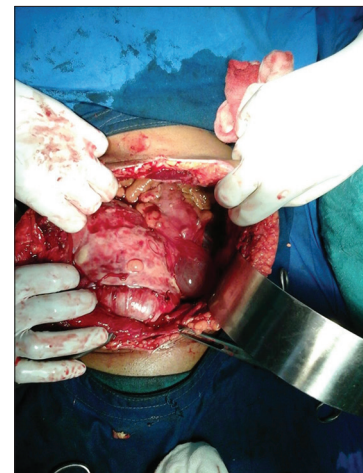

Figure 2: Adhesions were present with restricted mobility



Figure 3: Cut section of the specimen showing cyst consisting of sebaceous material with tuft of hair and multiple teeth

Cystic fluid showed occasional degenerated cells over a proteinaceous background which gave the impression of oleo-keratin granulomatosis. The patient was discharged on the 8th post-operative day. Her post-operative period was uneventful.

CONCLUSION

Dermoid cyst is the most common benign tumor of the ovary, occurring in the reproductive age group. The tumor though called dermoid represents elements of all the three germinal layers, i.e., ectoderm, endoderm, and mesoderm. Since the ectodermal element is more pronounced on histopathology, the term dermoid has stuck in the medical parlance. The malignant change in this benign tumor is very rare (approx. 1%) and the usual malignancy is squamous cell carcinoma and sarcoma if at all. The clinical picture of leaked/ruptured dermoid cyst produces a clinical picture of malignancy. The prognosis of this condition is otherwise quiet good, but the presentation is unique and occurrence quite rare.

REFERENCES

1. Kurrein F, Fothergill RJ. Oleo-keratin granuloma in peritoneum: A rare complication of ovarian dermoid. *J Obstet Gynaecol Br Commonw* 1961;68:124-7
2. Stuart GC, Smith JP. Ruptured benign cystic teratomas mimicking gynecologic malignancy. *Gynecol Oncol* 1983;16:139-43.
3. Suprasert P, Khunamornpong S, Siriaunkgul S, Phongnarisorn C, Siriaree S. Ruptured mature cystic teratomas mimicking advanced stage ovarian cancer: A report of 2 cases study. *J Med Assoc Thai* 2004;87:1522-5.
4. Phupong V, Sueblinvong T, Triratanachat S. Ovarian teratoma with diffused peritoneal reactions mimicking advanced ovarian malignancy. *Arch Gynecol Obstet* 2004;270:189-91.