Original Article

Role of Ultrasound & Computed Tomography Scan in Evaluation of Carcinoma Gall Bladder and its Histopathological Correlation: A Cross-Sectional Study

Prince, Samarth Arya

Rohilkhand, Medical College, Bareilly, Uttar Pradesh, India.

Corresponding author:
Samarth Arya
Rohilkhand, Medical College,
Bareilly, Uttar Pradesh, India.
Email: aryasamarth1@gmail.com

Received: 01.10.2024
Accepted: 16.11.2024

How to cite this article:
Prince, Arya S.
Role of Ultrasound & Computed Tomography Scan in Evaluation of Carcinoma Gall Bladder and its Histopathological Correlation: A Cross-Sectional Study. Int J Adv Integ Med Sci 2024;9(3):1-6.

Source of Support: Nil,
Conflicts of Interest: None declared.

ABSTRACT

Background: Carcinoma of the gallbladder is an aggressive malignancy with poor prognosis due to nonspecific symptoms and delayed diagnosis. Imaging plays a key role in detection and staging. Ultrasonography is commonly used as the initial modality, while computed tomography provides detailed assessment of tumor extent and metastasis. Correlation with histopathology is essential for diagnostic confirmation.

Methods: This hospital-based cross-sectional study was conducted in the Department of Radiodiagnosis, Rohilkhand Medical College and Hospital, Bareilly, over one year. Sixty-one newly diagnosed patients with gallbladder masses detected on ultrasonography were included. All patients underwent ultrasonography followed by contrast-enhanced computed tomography. Imaging findings were evaluated and correlated with histopathological examination. Statistical analysis was performed using SPSS version 23.0.

Results: Most patients were aged 40–59 years, with female predominance. Asymmetrical gallbladder wall thickening was the most common finding on both ultrasonography and computed tomography. Most lesions were hypoechoic on ultrasonography and hypodense with heterogeneous enhancement on computed tomography. CT detected lymph node involvement and distant metastasis more effectively than ultrasonography. No significant correlation was observed between imaging features and histopathological grade.

Conclusion: Ultrasonography and computed tomography have complementary roles in evaluating gallbladder carcinoma. Ultrasonography is effective for initial detection, while computed tomography is superior for staging. Histopathology remains the definitive diagnostic standard.

KEYWORDS: Carcinoma gallbladder, Ultrasonography, Computed tomography, Histopathological correlation, Diagnostic imaging, Cross-sectional study

INTRODUCTION

The gallbladder is a pear-shaped, sac-like organ situated in the gallbladder fossa on the inferior surface of the liver, in close anatomical relation to the duodenum, right kidney, and transverse colon.[1] Although small in size, malignancies arising from the gallbladder are associated with aggressive biological behavior and poor clinical outcomes. Gallbladder carcinoma (GBC) is an uncommon malignancy worldwide, accounting for approximately 1.2% of all cancers and nearly 1.7% of cancer-related mortality, reflecting its disproportionately high lethality.[2]

Gallbladder cancer demonstrates marked geographic and ethnic variation in incidence, largely influenced by environmental exposure, lifestyle factors, and genetic susceptibility.[3] India contributes a significant proportion of the global disease burden, with a higher prevalence observed in the northern, north-eastern, central, and eastern regions of the country.[4] In contrast to Western populations, gallbladder carcinoma in India commonly presents in the fifth and sixth decades of life and shows a distinct female predominance.[5] Cholelithiasis remains the most important predisposing factor and is reported in nearly 80% of affected Indian patients, while additional risk factors include advancing age, chronic inflammation, persistent infections, exposure to environmental toxins, and smoking.[6]

Clinically, gallbladder carcinoma poses a diagnostic challenge due to its insidious onset and non-specific symptomatology, which often overlaps with benign biliary conditions such as chronic cholecystitis and gallstone disease.[7] Patients may present with right upper quadrant

pain, jaundice, anorexia, weight loss, nausea, vomiting, or dark urine, while some remain asymptomatic until advanced stages.[8] The disease typically evolves over several years through a sequence of metaplasia, dysplasia, carcinoma in situ, and invasive carcinoma. The absence of a serosal layer facilitates early hepatic invasion and metastatic spread, resulting in a median survival of approximately six months and a five-year survival rate of less than 5%.[9]

Imaging plays a pivotal role in the detection, characterization, and staging of gallbladder carcinoma. Ultrasonography (USG) is widely employed as the initial imaging modality due to its accessibility, safety, and cost-effectiveness. It enables identification of gallbladder masses, focal or diffuse wall thickening, intraluminal lesions, mucosal disruption, and loss of the liver–gallbladder interface.[10] However, computed tomography (CT) is indispensable for comprehensive evaluation, providing superior delineation of tumor extent, hepatic infiltration, lymphadenopathy, vascular involvement, and distant metastases.[11] Typical CT patterns include intraluminal mass lesions, eccentric or diffuse wall thickening, and complete replacement of the gallbladder by tumor.

Correlation of imaging findings with histopathological diagnosis is essential for validating radiological accuracy, guiding staging, and optimizing therapeutic decision-making. Therefore, the study aimed to evaluate the role of ultrasonography and computed tomography in the assessment of gallbladder carcinoma and to correlate imaging features with histopathological findings.

MATERIAL AND METHODS

This hospital-based cross-sectional study was conducted in the Department of Radiodiagnosis at Rohilkhand Medical College and Hospital, Bareilly, over a period of one year. Prior to commencement, approval was obtained from the Institutional Ethics Committee, and written informed consent was secured from all participants.

The sample size was determined using a confidence level of 96% and an allowable error of 5%, as described in the methodology by Patel et al., yielding a final sample size of 61 patients. Newly diagnosed patients of either sex with a gallbladder mass detected on ultrasonography and who were willing to undergo further imaging evaluation were included in the study. Patients with a history of prior gallbladder surgery, pregnant women, individuals with known hypersensitivity to iodinated contrast material, those who declined consent for computed tomography, and patients who did not undergo surgical intervention with histopathological confirmation were excluded.

All patients initially underwent transabdominal ultrasonography after fasting for 6–8 hours to ensure optimal gallbladder distension. Examinations were performed with the patient in the supine or left lateral decubitus position. The gallbladder was systematically evaluated for wall thickness, focal or diffuse wall irregularity, intraluminal or exophytic mass lesions, and other associated morphological abnormalities.

Subsequently, contrast-enhanced computed tomography of the entire abdomen was performed in all patients after confirming normal renal function. Multiphase imaging was obtained, including arterial, portal venous and delayed phases, to allow comprehensive assessment. Computed tomography images were analyzed for gallbladder wall thickening, mass lesions, hepatic infiltration, lymph node involvement, and extension to adjacent organs.

Ultrasonographic and computed tomography findings were independently reviewed and analyzed to identify imaging features suggestive of gallbladder malignancy. Radiological findings were then correlated with histopathological examination of surgical specimens, which served as the reference standard for confirmation of carcinoma gallbladder.

Ultrasonography examinations were performed using Samsung V7, HS70, HS40, and RS80 machines, while computed tomography scans were acquired using 16-slice and 128-slice GE CT scanners available in the department. Statistical analysis was performed using the Statistical Package for Social Sciences (SPSS), version 23.0. Descriptive statistics were expressed as mean ± standard deviation and percentages. Appropriate statistical tests were applied, and a p-value of less than 0.05 was considered statistically significant.

RESULTS

In the present study, Table 1 shows that gallbladder carcinoma was most commonly observed in patients aged 40–59 years, with a clear predominance among females, indicating higher disease burden in middle-aged women within the study population.

Table 1: Baseline Demographic Characteristics of the Study Population (n = 61)

Category	Variable	Number (n)	Percentage (%)
Age Group (years)	< 40	10	16.4
	40–59	29	47.5
	≥ 60	22	36.1
Gender	Female	42	68.9
	Male	19	31.1

In Table 2, asymmetrical gallbladder wall thickening was the most frequent ultrasonographic finding, and the majority of lesions were hypoechoic, supporting an infiltrative malignant pattern identifiable on ultrasound.

Table 2: Ultrasonographic Characteristics of Gallbladder Lesions (n = 61)			
Ultrasonographic feature	**Category**	**Number (n)**	**Percentage (%)**
Morphology	Asymmetrical wall thickening	36	59.0
	Intraluminal mass	13	21.3
	Mass replacing gallbladder	12	19.7
Echogenicity	Hypoechoic	54	88.5
	Hyperechoic	7	11.5

In Table 3, computed tomography predominantly demonstrated asymmetrical wall thickening with hypodense attenuation and heterogeneous enhancement, reflecting necrosis and irregular tumor vascularity typical of gallbladder carcinoma.

Table 3: Computed Tomography Characteristics of Gallbladder Lesions (n = 61)			
CT feature	**Category**	**Number (n)**	**Percentage (%)**
Morphology	Asymmetrical wall thickening	36	59.0
	Intraluminal mass	15	24.6
	Mass replacing gallbladder	10	16.4
Attenuation	Hypodense	54	88.5
	Hyperdense	6	9.8
	Isodense	1	1.6
Enhancement pattern	Heterogeneous	56	91.8
	Homogeneous	5	8.2

In Table 4, a strong and statistically significant concordance was observed between ultrasonographic and CT morphological patterns, indicating reliable agreement between both imaging modalities in lesion characterization.

Table 4: Correlation Between Ultrasonographic and CT Morphology of Gallbladder Lesions (n = 61)				
USG morphology \ CT morphology	**Asymmetrical wall thickening**	**Intraluminal mass**	**Mass replacing gallbladder**	**Total**
Asymmetrical wall thickening	31	4	1	36
Intraluminal mass	4	9	0	13
Mass replacing gallbladder	1	0	11	12
Total	36	13	12	61

Chi-square = 56.3, df = 4, $p < 0.001$

In Table 5, Computed tomography identified abdominal lymph nodes and distant metastases more frequently than ultrasonography, underscoring its superior sensitivity for staging and assessment of disease spread.

Table 5: Detection of Lymph Nodes and Distant Metastasis by Ultrasonography and CT (n = 61)			
Parameter	**USG positive**	**CT positive**	**Statistical significance**
Abdominal lymph nodes	53 (86.9%)	59 (96.7%)	$\chi^2 = 13.7$, $p < 0.001$
Distant metastasis	41 (67.2%)	61 (100%)	CT superior

In Table 6, No statistically significant association was noted between imaging features and histopathological grade, suggesting that radiological findings reflect tumor extent rather than cellular differentiation.

Table 6: Imaging–Histopathological Correlation in Gallbladder Carcinoma (n = 61)		
Imaging parameter	**Histopathological finding**	**Statistical significance**
CT morphology vs grade	No significant correlation	p = 0.302
USG morphology vs grade	No significant correlation	p = 0.559
CT enhancement vs grade	No significant correlation	p = 0.373
CT attenuation vs grade	No significant correlation	p = 0.232

In Table 7, both ultrasonography and computed tomography demonstrated high diagnostic accuracy in detecting gallbladder carcinoma, with CT showing slightly higher sensitivity and overall accuracy.

Table 7: Diagnostic Performance of Ultrasonography and Computed Tomography in Detection of Gallbladder Carcinoma		
Parameter	**Ultrasonography (%)**	**Computed Tomography (%)**
Sensitivity	95.0	98.4
Specificity	100.0	100.0
Positive predictive value	100.0	98.3
Negative predictive value	0.0	0.0
Diagnostic accuracy	95.1	98.4

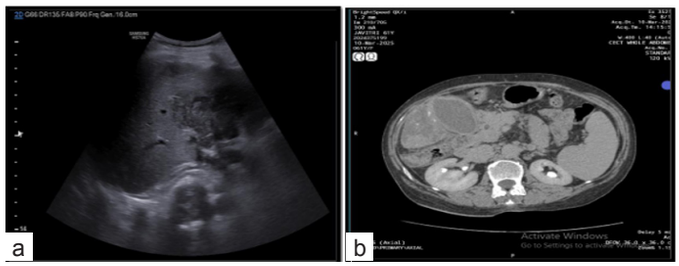

Fig. 1: (a) Transabdominal ultrasonography features in a 61 yr old female reveals diffuse circumferential wall thickening. (b) Axial CECT scan of same patient reveals same diffuse circumferential enhancing soft tissue wall thickening with infiltration into the adjacent liver segments. This suggest the diagnosis of carcinoma gall bladder.



Fig. 2: (a) Transabdominal ultrasonography features in a 57-year-old male reveals ill-defined heterogeneously hypoechoic mass lesion in GB fossa region with GB calculus. (b) Axial CECT scan of same patient reveals same ill-defined heterogeneously enhancing mass lesion in the GB fossa completely replacing the gallbladder and lesion is infiltrating into adjacent liver segment. This suggest the diagnosis of carcinoma gall bladder.

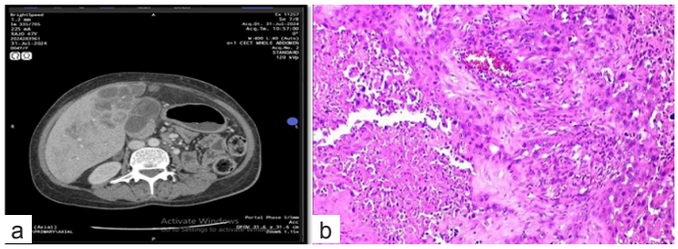

Fig. 3: (a) Axial CECT scan of a 47-year-old female reveals eccentric wall thickening in the posterior wall of gallbladder neck showing heterogeneous enhancement. Fat planes with adjacent segment IVB of the liver are indistinct, and a GB calculus is seen. (b) Histopathology section tissue from same patient suggestive of poorly differentiated adenocarcinoma gall bladder.

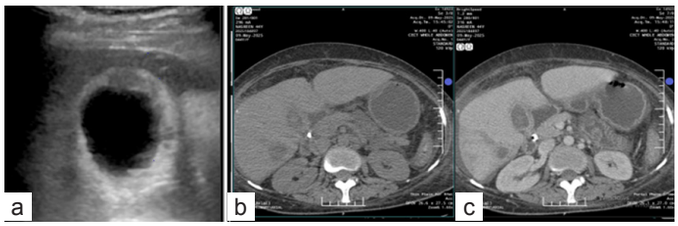

Fig. 4: (a) Transabdominal ultrasonography features in a 44-year-old female reveals diffuse asymmetrical wall thickening at neck and fundal region. (b) & (c) Axial plain & contrast enhanced CT scan of same patient reveals same GB wall appears slightly thickened in the neck & fundus region with loss of fat plane with adjacent liver parenchyma in the fundal region. This suggest the diagnosis of carcinoma gall bladder.

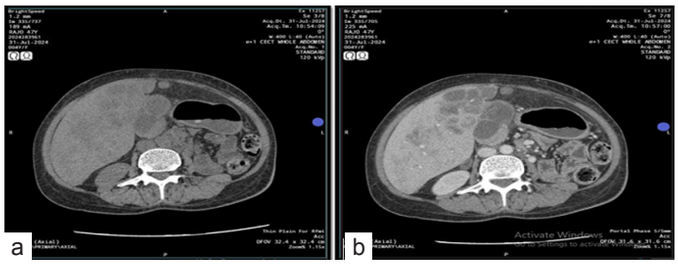

Fig. 5: (a) & (b) Axial plain & contrast enhanced CT scan of 47-year-old female reveals GB is overdistended with multiple hyperdense calculi in the GB lumen. Eccentric wall thickening in the posterior wall of gallbladder neck showing heterogeneous enhancement. Fat planes with adjacent segment IVB of liver is indistinct. This suggest the diagnosis of carcinoma gall bladder.

DISCUSSION

In the present study, gallbladder carcinoma was most frequently observed in patients aged 40–59 years, followed by those above 60 years. Patel S et al. (2019)[12] reported that more than half of their patients were between 30 and 50 years of age, while Mohakud et al. (2022)[13] documented mean ages of 54.7 years in females and 58 years in males. Ghafoor et al. (2017)[14] observed a mean age of approximately 60 years, and Nahid N et al. (2024)[15] reported the highest proportion of cases in the 51–60-year age group. These findings suggest that gallbladder carcinoma commonly manifests after prolonged exposure to gallstones and chronic inflammatory insults. The predominance of female patients in the present study reflects observations by Patel S et al. (2019)[12], Mohakud et al. (2022)[13], and Rout et al. (2021),[16] all of whom reported a significantly higher incidence among females, attributed to hormonal factors and increased gallstone prevalence.

Ultrasonographic evaluation in the present study showed asymmetrical gallbladder wall thickening as the most frequent morphological abnormality, followed by intraluminal masses and gallbladder-replacing lesions. Jindal G et al. (2018)[17] described irregular wall thickening and polypoidal lesions as common imaging findings in gallbladder carcinoma. Mohakud et al. (2022)[13] reported a higher proportion of gallbladder-replacing masses, reflecting more advanced disease at presentation. Ghafoor et al. (2017)[14] documented irregular mural thickening in a substantial proportion of cases. The predominance of mural thickening in the present study suggests detection at an infiltrative stage rather than as a bulky mass. Hypoechoic echogenicity was the dominant sonographic feature, reflecting dense cellularity and necrosis, as also described by Ghafoor et al. (2017)[14] and Khanduri S et al. (2018).[18]

Computed tomography findings in the present study demonstrated asymmetrical wall thickening as the most common morphological pattern, followed by intraluminal masses and lesions replacing the gallbladder. Jindal G et al. (2018)[17] and Maldonado CZ et al. (2014)[19] identified mural thickening as the predominant CT finding, while Mohakud et al. (2022)[13] reported variable proportions of mass-forming and infiltrative lesions. A statistically significant correlation between ultrasonographic and CT morphology observed in this study indicates that ultrasonography effectively identifies gallbladder lesions, whereas CT provides more accurate delineation of lesion extent and infiltration.

Analysis of echogenicity and CT attenuation revealed that most hypoechoic lesions corresponded to hypodense attenuation, although no statistically significant association was demonstrated. Ghafoor et al. (2017)[14] noted that hypoechoic lesions often appear hypodense on CT due

to necrosis and poor vascularity. Jindal G et al. (2018)[17] emphasized that attenuation patterns vary depending on tumor composition and cannot reliably predict histological behavior. Similarly, enhancement analysis in the present study showed predominantly heterogeneous enhancement without a significant association with echogenicity. Tang et al. (2018)[20] reported heterogeneous enhancement in malignant gallbladder lesions on both contrast-enhanced ultrasonography and CT, reflecting irregular vascularity and necrosis.

CT demonstrated higher sensitivity than ultrasonography in detecting lymph node involvement and distant metastasis in the present study. Patel S et al. (2019)[12] highlighted CT's superior ability to detect nodal disease and hepatic involvement. Jindal G et al. (2018)[17] reported accurate identification of lymphadenopathy and adjacent organ invasion on CT, while Khanduri S et al. (2018)[18] noted that ultrasonography may underestimate deep-seated nodal disease. These findings reinforce the role of CT in accurate staging and preoperative assessment.

Histopathological evaluation in the present study revealed well-differentiated adenocarcinoma as the most common tumor type, followed by moderately and poorly differentiated tumors. No statistically significant correlation was observed between imaging morphology, enhancement pattern, or attenuation characteristics and histopathological grade. Patel S et al. (2019)[12] reported that imaging features could not reliably predict tumor differentiation, while Mohakud et al. (2022)[13] similarly found no consistent relationship between imaging morphology and histological grade. These observations emphasize that imaging primarily reflects macroscopic tumor extent rather than cellular differentiation.

Both ultrasonography and computed tomography demonstrated high diagnostic accuracy in detecting carcinoma gallbladder, with CT showing marginally higher sensitivity and overall accuracy. Ghafoor et al. (2017)[14] reported CT sensitivity exceeding 95%, while Khanduri S et al. (2018)[18] demonstrated good diagnostic performance of ultrasonography in identifying malignant gallbladder lesions. The findings of the present study reinforce the role of ultrasonography as an effective initial diagnostic modality and highlight the indispensable contribution of CT in comprehensive evaluation.

CONCLUSION

We concluded that ultrasonography and computed tomography have complementary roles in the evaluation of carcinoma gallbladder. Ultrasonography is a reliable and cost-effective initial imaging modality for detecting gallbladder lesions and morphological abnormalities, whereas computed tomography offers superior assessment of disease extent, lymph node involvement, and distant metastasis, facilitating accurate staging and management planning. Although imaging findings aid diagnosis and staging, histopathological examination remains the definitive method for confirmation and grading of gallbladder carcinoma.

REFERENCES

1. Vakili K, Pomfret EA. Biliary anatomy and embryology. Surg Clin North Am. 2008;88(6):1159-74.
2. Hundal R, Shaffer EA. Gallbladder cancer: epidemiology and outcome. Clin Epidemiol. 2014;6:99-109.
3. Lazcano-Ponce EC, Miquel JF, Muñoz N, Herrero R, Ferreccio C, Wistuba II, et al. Epidemiology and molecular pathology of gallbladder cancer. CA Cancer J Clin. 2001;51(6):349-64.
4. Dutta U, Bush N, Kalsi D, Popli P, Kapoor VK. Epidemiology of gallbladder cancer in India. Chin Clin Oncol. 2019;8(4):33.
5. Gupta S, Kori C, Kumar V, Misra S, Akhtar N. Epidemiological study of gallbladder cancer patients from North Indian Gangetic plains: a high-volume centre's experience. J Gastrointest Cancer. 2016;47(1):27-35.
6. Shukla VK, Khandelwal C, Roy SK, Vaidya MP. Primary carcinoma of the gall bladder: a review of a 16-year period at the university hospital. J Surg Oncol. 1985;28(1):32-5.
7. Pandey M, Pathak AK, Gautam A, Aryya NC, Shukla VK. Carcinoma of the gallbladder. Dig Dis Sci. 2001;46(6):1145-51.
8. Nandakumar A. National cancer registry programme: consolidated report of the population-based cancer registries. New Delhi: Indian Council of Medical Research; 1990.
9. Hederström E, Forsberg L. Ultrasonography in carcinoma of the gallbladder: diagnostic difficulties and pitfalls. Acta Radiol. 1987;28(6):715-8.
10. Levy AD, Murakata LA, Rohrmann CA Jr. Gallbladder carcinoma: radiologic-pathologic correlation. Radiographics. 2001;21(2):295-314.
11. Patel S, Patel S, Bhatia V, Chauhan B, Vadhiya R. Ca gallbladder: comparing role of USG and CT scan in staging of the disease. Int J Sci Res. 2019;9(4):15-8.
12. Mohakud S, Sidhu S, Deep N, Naik S. Panorama of multidetector-row computed tomography findings of carcinoma gallbladder: a retrospective observational study. J Cancer Res Ther. 2022;18(3):661-7.
13. Ghafoor N, Abedin N, Mohiuddin AS. Role of ultrasound and computed tomography in the evaluation of gallbladder malignancy. Anwer Khan Mod Med Coll J. 2017;8(2):105-11.
14. Nahid N, Niaj P, Santoshi. Validity of computed tomography in diagnosing gallbladder masses and correlation with fine-needle aspiration cytology and histopathological examination in a teaching hospital in northeast India. Indian J Appl Res. 2024;14(4). [Page numbers to be verified]
15. Rout N, Hota SK, Dash S, Samantaray S, Mallik RN, Agrawal O. Diagnostic utility of ultrasound-guided fine-needle aspiration cytology in gallbladder lesions: an experience from a tertiary care cancer center in Eastern India. J Cytol. 2021;38(3):145-50.

16. Jindal G, Singal S, Nagi B, Mittal A, Mittal S, Singal R. Role of multidetector computed tomography in evaluation of gallbladder malignancy and its pathological correlation in an Indian rural center. Maedica (Bucur). 2018;13(1):55-60.

17. Khanduri S, Goyal A, Usmani T, Jain S, Goyal A, Chaudhary M, et al. Role of ultrasonography in the diagnosis of gallbladder carcinoma: a boon for low-resource settings. Asian J Oncol. 2018;4(1):1-5.

18. Maldonado CZ, Lopez MJ, Valverde FM, Soldevilla FA, Quirante FP, Medina VG. Ultrasound findings associated with gallbladder carcinoma. Cir Esp. 2014;92(5):348-55.

19. Zhong J, Su Z, Zhang Y, Zhang H, Lin P, Tang X, et al. Contrast-enhanced ultrasonography versus contrast-enhanced computed tomography for assessment of residual tumor from hepatocellular carcinoma treated with transarterial chemoembolization: a meta-analysis. J Ultrasound Med. 2018;37(8):1881-90.

© The Author(s). 2024 Open Access. This article is distributed under the terms of the Creative Commons Attribution 4.0 International License (https://creativecommons.org/licenses/by-nc/4.0/), which permits unrestricted use, distribution, and non-commercial reproduction in any medium, provided you give appropriate credit to the original author(s) and the source, provide a link to the Creative Commons license, and indicate if changes were made. The Creative Commons Public Domain Dedication waiver (http://creativecommons.org/publicdomain/ zero/1.0/) applies to the data made available in this article, unless otherwise stated.