ORIGINAL ARTICLE

Role of Ultrasonography in Early Detection of Complications Dengue Fever: A Cross-Sectional Study

Kriti Gupta, Saras Mittal, Phaneendra Kolla

Department of Radiodiagnosis, Rohilkhand medical college, Bareilly, Uttar Pradesh, India

Corresponding author:
Saras Mittal, Junior resident,
Department of Radiodiagnosis
Rohilkhand medical college, Bareilly
Email: Sarasmittal9090@gmail.com

Received: 01.09.2024
Accepted: 20.09.2024

How to cite this article:
Gupta K, Mittal S.
Role of Ultrasonography in Early Detection of Complications in Dengue Fever A Cross-Section Study. Int J Adv Integ Med Sci 2024;9(3):17-20.

Source of Support: Nil,
Conflicts of Interest: None declared.

ABSTRACT

Introduction: Dengue fever is a significant health issue, with early detection of complications crucial for effective management. Ultrasonography (USG) helps identify complications like organomegaly and fluid accumulation.

Objectives: To identify ultrasonographic markers of complications such as pleural effusion, ascites, hepatomegaly, splenomegaly, and gallbladder wall thickening in dengue fever and determine the demographic profile of patients.

Methods: A cross-sectional study was conducted at Rohilkhand Medical College and Hospital (Nov 2023–Oct 2024) with 87 dengue patients. USG findings and blood test results were analyzed using SPSS v25.0.

Results: Gallbladder wall thickening was the most common finding, followed by hepatomegaly, splenomegaly, ascites, and pleural effusion. Severe cases had higher incidences of organomegaly and fluid accumulation. 60.9% of participants tested positive for Dengue NS1 alone (P=0.011).

Conclusion: USG is a crucial tool for early detection of dengue complications. Identifying abnormalities like gallbladder thickening and pleural effusion early improves patient management.

KEYWORDS: Dengue fever, ultrasonography, complications, gallbladder thickening, hepatomegaly, pleural effusion, early diagnosis.

INTRODUCTION

Dengue fever, caused by the dengue virus, remains a significant global health concern, particularly in tropical and subtropical regions, including India. The disease is transmitted primarily by Aedes mosquitoes, with four distinct serotypes contributing to its complexity and varied clinical presentations.[1] Clinical manifestations can range from mild flu-like symptoms to severe conditions such as dengue hemorrhagic fever (DHF) and dengue shock syndrome (DSS).[2] In India, dengue continues to pose a major challenge to public health, with frequent outbreaks during the monsoon season.[3]

Ultrasonography has emerged as a useful diagnostic tool for detecting complications associated with dengue fever. Abdominal and chest ultrasonography, in particular, has been shown to predict disease progression in nonsevere cases by identifying abnormalities such as hepatomegaly, splenomegaly, and fluid accumulation.[4] Radiological evaluation is crucial for detecting complications such as internal bleeding and organ damage, which are often seen in more severe forms of the disease.[5] Furthermore, recent studies have highlighted the role of ultrasonography in assessing the complications of dengue hemorrhagic fever, including vascular leakage and organ involvement.[6]

Despite its potential, there are still gaps in diagnostic strategies, particularly regarding the timely identification of complications in resource-limited settings. Ultrasonography, as a non-invasive and cost-effective tool, offers an opportunity to bridge these gaps, but its full potential in early detection remains underexplored.[7,8] With increasing outbreaks of dengue, especially in India, it is essential to explore and validate the role of ultrasonography in improving diagnostic outcomes and patient management.[9,10]

This study aims to investigate the role of ultrasonography in early detection of complications in dengue fever, with the goal of enhancing diagnostic accuracy and improving patient outcomes in this region.

MATERIALS AND METHODS

This cross sectional study entitled "Role Of Ultrasonography In Early Detection Of Complications In Dengue Fever:-A Cross- Sectional Study" was conducted after clearance from Board of Studies and Ethical committee in the Department of Radiodiagnosis, Rohilkhand Medical college and Hospital, Bareilly, U.P. during the period 01 November 2023 to 31 October 2024.

Sample Size: 87 Cases

Sampling technique: Simple random sampling method was used to include the sample in the study

Inclusion and Exclusion criteria

The study subjects were chosen as per the inclusion and exclusion criteria:

Inclusion criteria

- Serologically diagnosed cases of dengue fever.

Exclusion criteria

- Patients not willing to give consent.
- Patients having thrombocytopenia due to causes other than dengue.
- Serologically negative for dengue.

Statistical analysis

Data were analyzed using SPSS version 25.0. Numerical data were presented as mean ± SD, categorical data as percentage and frequency. Student t-test and chi-square test were used, with $p<0.05$ for significance.

RESULTS

Table 1: Distribution of USG Findings with Clinical Severity

USG Findings	Dengue Fever (n=43)	Dengue Hemorrhagic Fever (n=30)	Dengue Shock Syndrome (n=14)
Gallbladder Wall Thickening	16	14	13
Hepatomegaly	10	12	8
Splenomegaly	7	6	4
Ascites	6	6	3
Pleural Effusion	4	7	8
Total	43	30	14

Table 1 shows the distribution of ultrasonographic (USG) findings across clinical severity levels of dengue revealed that gallbladder wall thickening was the most common finding in all categories, observed in 16 cases of dengue fever, 14 cases of dengue hemorrhagic fever, and 13 cases of dengue shock syndrome. Hepatomegaly was noted in 10, 12, and 8 cases across the respective groups, while splenomegaly was identified in 7 cases of dengue fever, 6 cases of dengue hemorrhagic fever, and 4 cases of dengue shock syndrome. Ascites was present in 6 cases each of dengue fever and dengue hemorrhagic fever and 3 cases of dengue shock syndrome. Pleural effusion was observed in 4 cases of dengue fever, 7 cases of dengue hemorrhagic fever, and 8 cases of dengue shock syndrome. The total number of participants in the study was 87, distributed as 43 with dengue fever, 30 with dengue hemorrhagic fever, and 14 with dengue shock syndrome.

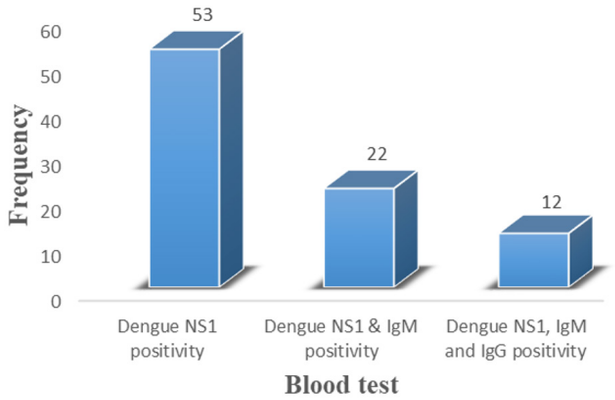

Figure 1: Distribution of study groups according to Blood Test Positivity:

In Figure 1, the distribution of study participants based on blood test positivity showed that the majority, 60.9% (53 participants), tested positive for Dengue NS1 alone. This was followed by 25.3% (22 participants) who tested positive for both Dengue NS1 and IgM, and 13.8% (12 participants) who tested positive for Dengue NS1, IgM, and IgG. The total number of participants was 87, and the blood test positivity distribution was statistically significant, with a P-value of 0.011.

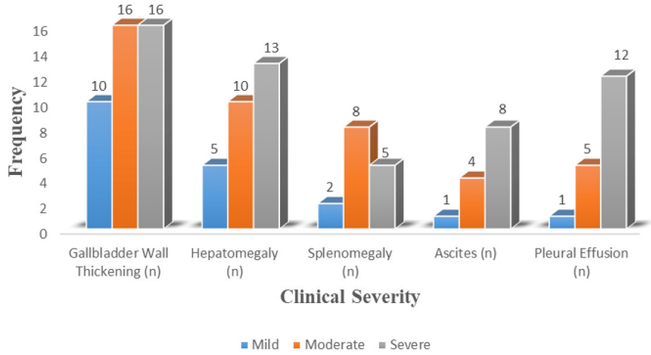

Figure 2: Distribution of USG Findings with Clinical Severity in Dengue Fever Patients

In Figure 2 the distribution of ultrasonographic (USG) findings with clinical severity in dengue fever patients revealed varying patterns across severity levels. Gallbladder wall thickening was observed in 10 mild cases, 16 moderate cases, and 16 severe cases, for a total of 42 participants. Hepatomegaly was seen in 5 mild, 10 moderate, and 13 severe cases, totaling 28 participants.

Splenomegaly was present in 2 mild, 8 moderate, and 5 severe cases, totaling 15 participants. Ascites was identified in 1 mild, 4 moderate, and 8 severe cases, amounting to 13 participants in total. Pleural effusion was detected in 1 mild, 5 moderate, and 12 severe cases, with a total of 18 participants. The total number of participants in the study was 87, distributed as 19 with mild severity, 43 with moderate severity, and 25 with severe disease.

Table 2: Distribution of Normal and Abnormal USG Findings in Dengue Fever Patients

USG Findings	Number of Patients (n)	Percentage (%)
Normal USG Findings	12	13.8
Abnormal USG Findings	75	86.2
Total	87	100%

Table 2 Shows the distribution of normal and abnormal ultrasonographic (USG) findings in dengue fever patients showed that 13.8% (12 participants) had normal USG findings, while the majority, 86.2% (75 participants), had abnormal USG findings. The total number of participants in the study was 87.

Table 3: Distribution of Single and Multiple Abnormalities on USG in Dengue Fever Patients.

USG Findings	Number of Patients (n)	Percentage (%)
Abnormal USG Findings	75	86.2
→ Single Abnormality	40	46
→ Multiple Abnormalities	35	40.2
Total	87	100%

In Table 3 the distribution of single and multiple abnormalities on ultrasonography (USG) in dengue fever patients indicated that 86.2% (75 participants) had abnormal USG findings. Among these, 46.0% (40 participants) had a single abnormality, while 40.2% (35 participants) had multiple abnormalities. The total number of participants in the study was 87.

DISCUSSION

The distribution of ultrasonographic findings in the study revealed that gallbladder wall thickening was the most common finding across all clinical severity levels of dengue, observed in 16 cases of dengue fever, 14 cases of dengue hemorrhagic fever (DHF), and 13 cases of dengue shock syndrome (DSS). Hepatomegaly and splenomegaly followed as frequent findings, with varying frequencies across severity levels. These findings are consistent with the study by Phadungsombat et al. (2024),[11] which identified liver and spleen involvement as common ultrasonographic features in dengue patients, particularly in cases with severe disease. Similarly, Sam et al. (2023)[12] noted the prevalence of organomegaly and fluid accumulation in dengue, with a higher incidence of pleural effusion and ascites in severe cases. However, our study uniquely found pleural effusion in a higher proportion of DSS cases, which contrasts with some findings from Sam et al. (2023),[12] where pleural effusion was more common in moderate dengue cases. The study also reported that 60.9% of participants tested positive for Dengue NS1 alone, similar to findings from Singh et al. (2023),[9] who also highlighted the dominance of NS1 positivity during acute dengue. In terms of ultrasonographic abnormalities, the majority of participants (86.2%) had abnormal findings, with 46% exhibiting a single abnormality and 40.2% showing multiple abnormalities. These figures align with Mustafa et al. (2023),[10] who found multiple organ involvement in the majority of dengue cases. The study's statistically significant distribution (P=0.011) of blood test positivity underscores the importance of early diagnostic tools, as emphasized by Singh et al. (2023)[9] and Phadungsombat et al. (2024).[11]

CONCLUSION

This study underscores the significant role of ultrasonography in the early detection of complications in dengue fever, with gallbladder wall thickening being the most prevalent finding across all clinical severity levels. Hepatomegaly, splenomegaly, ascites, and pleural effusion were also frequently observed, with their prevalence increasing in severe cases, highlighting the utility of ultrasonography for accurate assessment in clinical practice. The study further emphasizes that Dengue NS1 positivity was the most common in the study population, supporting its crucial role in early diagnosis and timely intervention. Statistically significant findings (P=0.011) also reinforce the importance of incorporating ultrasonography as an essential diagnostic tool in managing dengue fever. Moreover, the large proportion of abnormal ultrasonographic findings across participants indicates that early identification of these abnormalities can lead to better clinical outcomes, enabling healthcare providers to promptly address complications and improve patient management.

REFERENCES

1. Shamikumar RP, Mohammed S, Srinivasan C, Ananya TS. Evaluation of ultrasonography as an adjunct for diagnosis of dengue fever among children. Int J Med Rev Case Rep. 2023;7(4):57-62.
2. Manzoor N, Farooq SM, Sughra SKT, Siddiqi MI, Arooj S, Ishfaq A, et al. Role of ultrasonography in the diagnosis of dengue fever. Pak Biomed J. 2022;5(1):375-9.
3. Chaudhary S, Manrai K, Dhagat P, Dudeja P, Sen D, Grewal DS, et al. Abdominal and chest ultrasonography: a predictor for disease progression in nonsevere dengue. Med J Armed Forces India. 2023;79(4):386-91.

4. Akhtar S, Khatoon S, Raza M, Majeed AI, Shah SZ, Qazi A, et al. Radiological evaluation of various complications of dengue hemorrhagic fever. J Islamabad Med Dent Coll. 2024;13(2):277-82.
5. Namirimu T, Kim S. Dengue fever: epidemiology, clinical manifestations, diagnosis, and therapeutic strategies. Ann Clin Microbiol. 2024;27(2):131-41.
6. de Almeida MT, Merighi DG, Visnardi AB, Boneto Gonçalves CA, Amorim VM, Ferrari AS, et al. Latin America's dengue outbreak poses a global health threat. Viruses. 2025;17(1):57.
7. Al-Mamun M, Uzzal NI, Karim MZ, Alam M, Hoque T. Dengue outbreak and its threat to public health system: an insight into a growing concern in Bangladesh. Clin Epidemiol Glob Health. 2023;24:101456.
8. Lessa CL, Hodel KV, Goncalves MD, Machado BA. Dengue as a disease threatening global health: a narrative review focusing on Latin America and Brazil. Trop Med Infect Dis. 2023;8(5):241.
9. Singh N, Singh AK, Kumar A. Dengue outbreak update in India: 2022. Indian J Public Health. 2023;67(1):181-3.
10. Mustafa Z, Khan HM, Azam M, Sami H, Ali SG, Ahmad I, et al. Insight into the seroepidemiology and dynamics of circulating serotypes of dengue virus over a 4-year period in western Uttar Pradesh, India. Access Microbiol. 2023;5(6):000567.
11. Phadungsombat J, Nakayama EE, Shioda T. Unraveling dengue virus diversity in Asia: an epidemiological study through genetic sequences and phylogenetic analysis. Viruses. 2024;16(7):1046.
12. Sam AK, Mukhopadhyay S, Phuleria HC. Dengue in India: association with weather and socioeconomic variables. In: EGU General Assembly 2023; 2023 Apr 23-28; Vienna, Austria. Abstract EGU23-5666.

© The Author(s). 2024 Open Access. This article is distributed under the terms of the Creative Commons Attribution 4.0 International License (https://creativecommons.org/licenses/by-nc/4.0/), which permits unrestricted use, distribution, and non-commercial reproduction in any medium, provided you give appropriate credit to the original author(s) and the source, provide a link to the Creative Commons license, and indicate if changes were made. The Creative Commons Public Domain Dedication waiver (http://creativecommons.org/publicdomain/ zero/1.0/) applies to the data made available in this article, unless otherwise stated.