ORIGINAL ARTICLE

Guardian Genome Gone Rogue: Prognostic Significance of P53 Immunohistochemical Marker in Invasive Breast Carcinoma

Neha Singh[1], Mithila Bisth[2], Nitesh Mohan[3], Divya Bajpai[4]

[1]Junior Resident, [2]Professor, [3]Professor & HOD, [4]Associate professor

Department of Pathology, Rohilkhand Medical College, Bareilly, Uttar Pradesh, India

Corresponding author:
Neha Singh, Junior Resident
Department of Pathology,
Rohilkhand Medical College, Bareilly,
Uttar Pradesh, India.
Email: pathologyrmch@gmail.com

Received: 19.09.2024
Accepted: 20.10.2024

How to cite this article:
Singh N, Bisth M, Mohan N, Bajpai D. Guardian Genome Gone Rogue: Prognostic Significance of P53 Immunohistochemical Marker in Invasive Breast Carcinoma. Int J Adv Integ Med Sci 2024;9(3):7-10.

Source of Support: Nil,
Conflicts of Interest: None declared.

ABSTRACT

Background: Breast cancer, affecting 2.3 million people and causing 685,000 deaths annually, is the most prevalent cancer globally. Despite advances in detection and treatment, breast cancer remains a significant health issue. The P53 gene, vital for genomic stability, is frequently mutated in cancers, leading to tumor growth and worse outcomes. This study investigates P53 over-expression in different breast cancer types and its relationship with clinicopathological factors, aiming to improve treatment strategies and prognoses.

Objectives: To investigate the P53 biomarker profile in invasive breast carcinoma and its correlation with prognostic markers like grade, stage, tumor type, ER/PR/HER2neu status, and axillary lymph nodes.

Material & Methods: This cross-sectional study was a 1 year study conducted in the tertiary care centre in Uttar Pradesh between November 2022, to October 2023. The study population included 90 histologically proven cases of breast carcinoma that also had immunohistochemistry evaluation done.

Results: In our study lymphovascular invasion (LVI) is more common (64.4%) than perineural invasion (PNI, 28.9%). Most tumors are T2 stage (47.8%), with significant nodal involvement observed. A high percentage (87.8%) have a Ki67 proliferation index greater than 14%. The most frequent molecular classification is Her2 Enriched (27.8%). The sample is nearly evenly split between ER-negative (51.1%) and ER-positive (48.9%) tumors, with more PR-negative (61.1%) and HER2-negative (52.2%) cases.

In the study, 68.9% of subjects have positive p53 expression, with no significant association found between p53 expression and ER, PR, or HER2/neu status. A significant association was found between p53 expression and nodal stage (p-value 0.001). No significant link was observed between p53 expression and Ki67 levels or molecular classification.

Conclusion: The study highlights the importance of breast cancer immunohistochemistry and molecular classification for understanding cancer biology and developing targeted therapies. The P53 gene is identified as a significant diagnostic and predictive marker.

Keywords: Breast carcinoma; p53; Immunohistochemistry; HER2/neu; Prognosis.

INTRODUCTION

Breast cancer is the most common cancer worldwide, with 2.3 million cases and 685,000 deaths annually, primarily affecting women.[2] Risk factors include being female, age, estrogen exposure, and genetics, while early pregnancy and breastfeeding can reduce risk. Advances in diagnosis and targeted therapies are focusing on molecular markers like P53 and HER2/neu.[3]

The P53 gene, also known as TP53, is critical for genome integrity and DNA damage control2. Mutations in P53 are common in breast cancer, leading to the accumulation of mutant proteins detectable by immunohistochemistry. These mutations are linked to worse prognosis and aggressive disease. Mutant P53 promotes tumor growth and lacks tumor-suppressive functions, impacting processes like immune response, cell differentiation, and apoptosis. This study aims to evaluate P53 over-expression in various breast cancer types and its correlation with clinicopathological factors, to improve treatment responses and predict cancer recurrence.

MATERIAL AND METHODS

All histopathologically diagnosed cases of breast carcinoma received in the Department of Pathology at Rohilkhand Medical College and Hospital during the study period of one year. Sample Size of 90 cases, calculated using an anticipated utilisation proportion of 6% and an absolute error of 5%. Patients who received radiotherapy or chemotherapy were excluded and cases other than invasive breast carcinoma. Each case was analyzed, and a pre-validated proforma was completed. Various details were collected for each case, including: UHID number, Histo number, IHC number, Patient demographics- name, age, sex, marital status, clinical information- chief complaints, past history, family history, pathologic details Modified Nottingham Score and grade, lymphovascular invasion (LVI), perineural invasion (PNI), lymph node status and Staging information (pTNM staging). The proforma also includes ER, PR, Her2/Neu, P53 interpretation.

Tissue specimens were fixed in 10% neutral buffered formalin solution. All specimens were processed according to routine histopathology laboratory practice, Histopathology slides were made and interpretation was performed by skilled pathologist using the standard reporting protocols, modified Nottingham histology score was given along with the grades followed by immunohistochemical studies, which were performed using ER, PR, Her 2 Neu, Ki 67 and p53. Pathological TNM staging was done as per the American Joint Committee on Cancer (AJCC), 8th edition. Based on the tumor size and extent, the status of regional lymph node involvement and metastasis, including primary tumor (Tis - T4), status of a regional lymph node. (N0-N3), and distant metastases (M0 to M1) were determined by clinical anatomical stage (0 to IV). The final anatomical stage then determined the prognosis, which varies from the best (stage 0) to the worst (stage IV).

Statistical Analysis of data was done by Microsoft Excel and then imported into SPSS version 23 for analysis. The analysis included calculating frequencies, percentages, means, and standard deviations. Appropriate statistical tests were applied based on the data distribution and type. The study was conducted with informed consent from the patients and approval was obtained from the Institutional Ethics Committee (IEC) of Rohilkhand Medical College and Hospital, Bareilly.

RESULTS

The study's participants were predominantly aged 31-50, with the highest proportion being 41-50 years old (24.4%). Most subjects were married (94.4%), and the majority had no family history of cancer (86.7%). Tumors were more common in the left breast (58.9%) compared to the right (41.1%). Tumor size was typically large, with 55.6% of tumors measuring over 5 cm, and the most frequent tumor location was the upper outer quadrant (70.0%) Fig. 1. The majority of tumors were moderately differentiated, with 74.4% classified as Grade-II, while Grade-I and Grade-III tumors accounted for 12.2% and 13.3%, respectively.

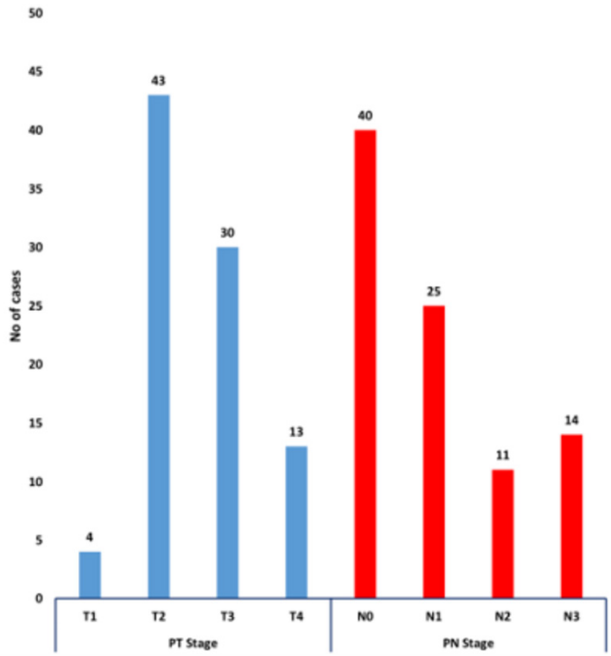

Fig. 1: Shows pathological Tumor(pT) and pathological nodal (pN) stage distribution of the cases

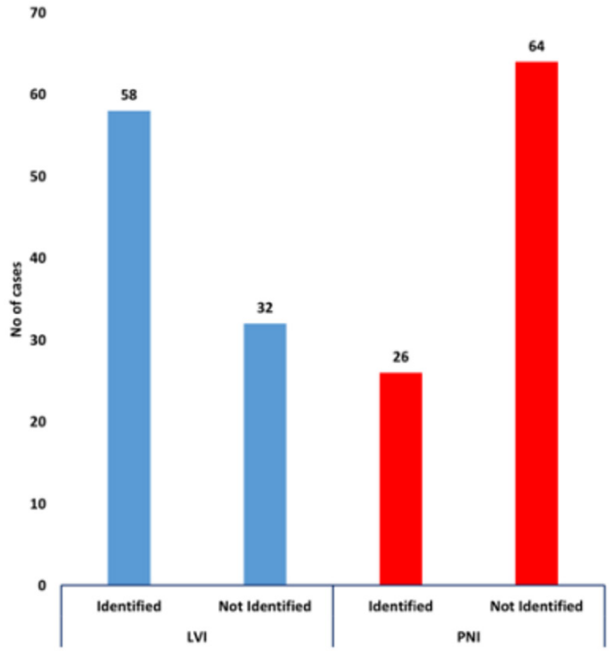

Fig. 2: Shows Lymphovascular invasion(LVI) and Perineural invasion (PNI)

Lymphovascular invasion was observed in 64.4% of cases, while perineural invasion was present in 28.9% Fig. 2. Most participants had T2 tumors (47.8%), followed by T3 (33.3%), and nearly half were at N0 nodal stage (44.4%).

A high Ki67 proliferation index, indicating aggressive tumor growth, was found in 87.8% of subjects. The most common molecular subtypes were Her2 Enriched (27.8%) and Triple Negative breast carcinoma (24.4%). Hormone receptor statuses were split, with 51.1% of tumors being ER-negative, and 61.1% were PR-negative. HER2-negative tumors were slightly more common (52.2%), with a small proportion having equivocal HER2 results (3.3%) Fig. 3.

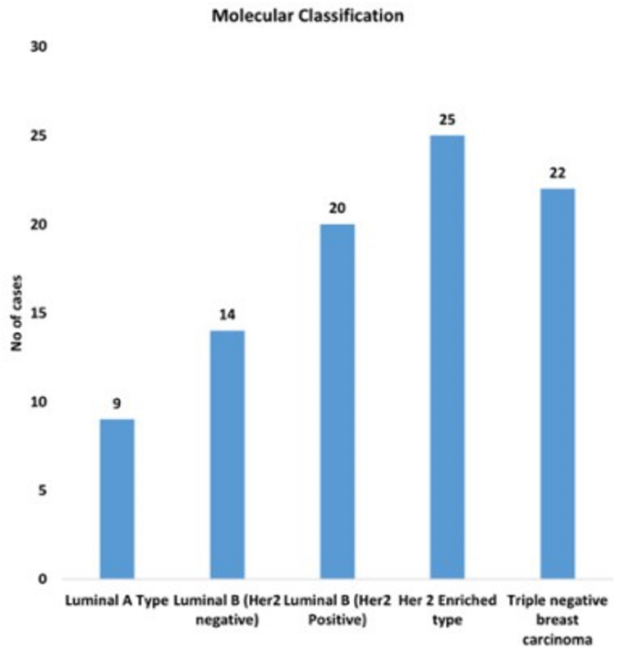

Fig. 3: Shows the molecular classification of the cases of invasive breast carcinoma

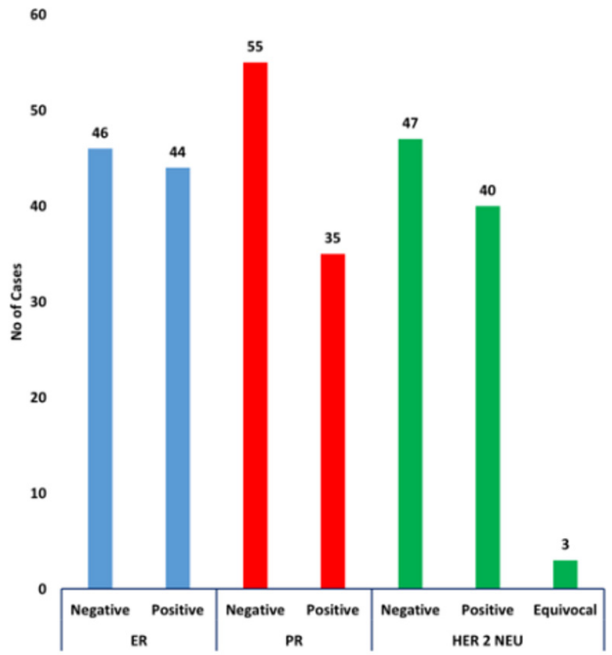

Fig. 4: Shows the hormonal Receptor status of the cases

Positive p53 expression was seen in 68.9% of cases, with no significant correlations found between p53 expression and hormone receptor status (ER, PR), HER2/neu status, age, tumor size, SBR grade, perineural invasion, Ki67 level, or molecular classification Fig. 5. There was a notable trend of decreased p53 expression with increasing age, though this was not statistically significant. However, a statistically significant association was observed between Nodal (N) stage and p53 expression, suggesting a potential link between p53 expression and lymph node involvement.

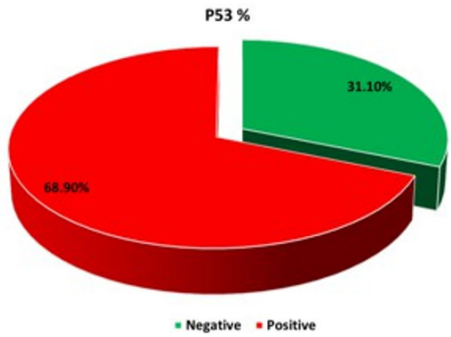

Fig. 5: Shows the p53 IHC staining results

DISCUSSION

The study's age distribution indicates that a significant number of participants are middle-aged, particularly between 41 to 50 years, with fewer participants in older age groups.[1] These findings align with previous research, which also found a peak in breast cancer cases among individuals in their late 40s.[2] Most participants were married (94.4%), and only a small percentage had a family history of cancer, aligning with previous studies that showed married women have a lower risk of breast cancer than unmarried women.[3]

In this study, Results give 86.7% without family history of cancer, indicating low familial cancer susceptibility.[4] Most patients presented with grade II tumors (74.4%), consistent with other studies.[5] Grade I tumors were less common (12.2%), and grade III tumors were found in 13.3% of cases. Lymphovascular invasion (LVI) was present in 69.4% of tumors, whereas perineural invasion (PNI) was found in 25.8%, contrasting with previous findings where PNI was rarer.[6] Tumors were predominantly staged as T2 (47.8%) and T3 (33.3%), with most being N0 (44.4%).[7] This distribution aligns with other studies but shows variation in P53 positivity and its relation to tumor stage and nodal involvement. The results highlight a spectrum of tumor characteristics and their implications for treatment and prognosis.

In this study, the majority of tumors were classified as HER2-enriched (27.8%) or triple-negative (24.4%), differing from other studies where triple-negative tumors were more prevalent.[8] The study found 48.9% of tumors were ER-positive, 38.9% PR-positive, and 44.4% HER2-positive (Figure 4). No significant correlations were found between p53 expression and ER, PR, or HER2

status, indicating that p53 expression may not be strongly linked to these markers in this population.[9] These findings underscore the need for individualized treatment plans based on molecular profiles and highlight the complexity of tumor biology, suggesting that p53 expression, while potentially prognostic, does not significantly correlate with hormone receptor or HER2 status in this study.[10]

The study investigates the relationship between p53 expression and various tumor characteristics, including age, molecular subtypes, and clinical stages. It finds that older patients with negative p53 expression might experience slower tumor progression, while younger patients with positive p53 expression may have more aggressive tumors.[11] p53 positivity was highest in Luminal B and HER2-enriched subtypes, but no significant correlation was found with molecular subtypes overall. The study also reveals a significant association between p53 expression and advanced tumor stages (T2 and T3) and higher nodal stages (N1), suggesting a link between p53 expression and tumor aggressiveness.[12] Additionally, there was no significant correlation between p53 expression and family cancer history. Although positive p53 expression was more common in grade II tumors, the association with tumor grade was not statistically significant. Overall, the study suggests that p53 expression could be a marker of tumor aggressiveness and may help guide treatment decisions, though further research is needed to fully understand its role in tumor biology.

CONCLUSION

The study highlights the importance of breast cancer immunohistochemistry and molecular classification for understanding cancer biology and developing targeted therapies. The P53 gene is identified as a significant diagnostic and predictive marker. Our study found a significant positive correlation between p53 overexpression and pTNM stage, indicating its relevance to metastatic disease and patient outcomes. The study highlights that p53 expression, along with hormone receptors, HER2-neu, and clinicopathological parameters, can aid in understanding prognostic markers and tailoring treatment for invasive breast carcinoma. p53 accumulation, particularly in Her2 Enriched type breast carcinoma, identifies a subgroup with high tumor aggressiveness and poor prognosis. Further research is needed to explore the complex interactions between biomarkers and demographic factors to enhance cancer management.

REFERENCES

1. Jindal B, Thakral RK, Mohan A, Ansari V, Sharma VK. Role of p53 as a prognostic marker in breast carcinoma and its correlation with tumor size, tumor grade and lymph node metastasis. Indian J Pathol Oncol. 2020;7(3):378-83.
2. Gnerlich JL, Deshpande AD, Jeffe DB, Sweet A, White N, Margenthaler JA. Elevated breast cancer mortality in women younger than age 40 years compared with older women is attributed to poorer survival in early-stage disease. J Am Coll Surg. 2009;208(3):341-7.
3. Colditz GA, Rosner BA, Speizer FE; Nurses' Health Study Research Group. Risk factors for breast cancer according to family history of breast cancer. J Natl Cancer Inst. 1996;88(6):365-71.
4. Rakha EA, Reis-Filho JS, Baehner F, Dabbs DJ, Decker T, Eusebi V, et al. Breast cancer prognostic classification in the molecular era: the role of histological grade. Breast Cancer Res. 2010;12(4):207.
5. Karak SG, Quatrano N, Buckley J, Ricci A Jr. Prevalence and significance of perineural invasion in invasive breast carcinoma. Conn Med. 2010;74(1):17-21.
6. Song HS, Rok Y, Kang S, Jeong KY, Kim YS. Prognostic significance of immunohistochemical expression of p53 gene product in operable breast cancer. Cancer Res Treat. 2006;38(4):218.
7. Dash SS, Sahu A, Toppo A. p53 expression in breast carcinoma and its association with tumor aggressiveness. J Datta Meghe Inst Med Sci Univ. 2021;16(2):266-72.
8. Martinazzi M, Crivelli F, Zampatti C, Martinazzi S. Relationship between p53 expression and other prognostic factors in human breast carcinoma: an immunohistochemical study. Am J Clin Pathol. 1993;100(3):213-7.
9. Zhou H, Shi R, Wei M, Zheng WL, Zhou JY, Ma WL. The expression and clinical significance of HERC4 in breast cancer. Cancer Cell Int. 2013;13(1):113.
10. Bertheau P, Lehmann-Che J, Varna M, Dumay A, Poirot B, Porcher R, et al. p53 in breast cancer subtypes and new insights into response to chemotherapy. Breast. 2013;22:27-9.
11. Olivier M, Langer A, Carrieri P, Bergh J, Klaar S, Eynard J, et al. The clinical value of somatic TP53 gene mutations in 1,794 patients with breast cancer. Clin Cancer Res. 2006;12(4):1157-67.

© The Author(s). 2024 Open Access. This article is distributed under the terms of the Creative Commons Attribution 4.0 International License (https://creativecommons.org/licenses/by-nc/4.0/), which permits unrestricted use, distribution, and non-commercial reproduction in any medium, provided you give appropriate credit to the original author(s) and the source, provide a link to the Creative Commons license, and indicate if changes were made. The Creative Commons Public Domain Dedication waiver (http://creativecommons.org/publicdomain/ zero/1.0/) applies to the data made available in this article, unless otherwise stated.