Case Report

Probable Pentalogy of Cantrell Associated with Acrania–Anencephaly Sequence and Cervical Spina Bifida: A Rare and Prenatal Diagnosis

Prince[1], Pramod Kumar[2]

[1]*Junior Resident,* [2]*Professor and Head*

Department of Radiodiagnosis, Rohilkhand Medical College and Hospital, Bareilly

Corresponding author:
Prince, Junior Resident
Department of Radiodiagnosis,
Rohilkhand Medical College and Hospital, Bareilly
Email: prince79764@gmail.com

Received: 19.02.2026
Accepted: 05.03.2026

How to cite this article:
Prince, Kumar P.
Probable Pentalogy of Cantrell Associated with Acrania–Anencephaly Sequence and Cervical Spina Bifida: A Rare and Prenatal Diagnosis. Int J Adv Integ Med Sci 2026;11(1):26-28.

Source of Support: Nil,
Conflicts of Interest: None declared.

ABSTRACT

Background: Pentalogy of Cantrell (POC) is an uncommon congenital malformation involving defects of the anterior abdominal wall, lower sternum, anterior diaphragm, diaphragmatic pericardium, and heart. The estimated incidence is approximately 1 in 65,000–200,000 live births. Association with severe neural tube defects such as acrania–anencephaly sequence and cervical spina bifida is exceptionally rare and may lead to diagnostic confusion.

Case Presentation: A 30-year-old primigravida at 23 weeks and 1 day of gestation was referred for detailed fetal anomaly evaluation. Targeted obstetric ultrasonography demonstrated absence of the calvarium with dysplastic brain tissue and bilateral prominent orbits (frog-eye sign), consistent with the acrania–anencephaly sequence. A posterior spinal defect involving the upper cervicothoracic spine suggested cervical spina bifida. A large membrane-covered anterior abdominal wall defect containing the heart, liver, gallbladder, stomach, and bowel loops was identified with umbilical cord insertion at the apex of the sac, consistent with a giant omphalocele and ectopia cordis. Based on these findings, a diagnosis of probable Pentalogy of Cantrell (Toyama Class II) was made. Post-delivery infantogram confirmed acrania, cervical spina bifida, and giant omphalocele.

Conclusion: The coexistence of ectopia cordis, giant omphalocele & NTD(Neural Tube Defects) should prompt consideration of POC(Pentalogy of Cantrell). Careful prenatal imaging allows early diagnosis, facilitates multidisciplinary counselling, and assists in pregnancy management.

KEYWORDS: Pentalogy of Cantrell; ectopia cordis; omphalocele; acrania; anencephaly; spina bifida; prenatal ultrasonography

INTRODUCTION

Pentalogy of Cantrell (POC) is a rare developmental anomaly initially described by Cantrell et al. in 1958. It is characterized by five defects involving the supraumbilical abdominal wall, lower sternum, anterior diaphragm, diaphragmatic pericardium & congenital heart.[1] The syndrome is believed to result from abnormal differentiation of ventral mesoderm between the fourteenth and eighteenth day of embryogenesis.[1,3]

Toyama classified the syndrome into three categories: complete (Class I), probable (Class II), and incomplete (Class III).[2] Because of variable phenotypic expression, many cases are initially mistaken for isolated omphalocele or ectopia cordis. Neural tube defects have only rarely been described in association with Pentalogy of Cantrell. We report a rare prenatal case of probable Pentalogy of Cantrell (POC) associated with acrania–anencephaly sequence and cervical spina bifida diagnosed on antenatal ultrasonography and confirmed by postnatal radiography.[3]

CASE REPORT

A 30-year-old woman, G1P1L0, attended the Department of Obstetrics and Gynaecology for routine antenatal care. Her last menstrual period was 1 December 2024, corresponding to a gestational age of 23 weeks and 1 day. She was referred to the Department of Radiodiagnosis for USG fetal well-being assessment.

No history of maternal diabetes mellitus, consanguinity, teratogenic drug intake, radiation exposure, or significant family history of congenital malformations. Antenatal history was otherwise unremarkable.

USG Findings (Figure 1):

Detailed fetal ultrasonography revealed single live intrauterine fetus corresponding to 21weeks 3 days gestational age with complete absence of the cranial vault and irregular dysplastic brain tissue exposed to the amniotic cavity. Bilateral prominent orbital globes produced the classical frog-eye appearance, consistent with the acrania–anencephaly sequence. The posterior elements of the upper cervicothoracic vertebrae demonstrated widening with splitting of the spinous processes, suggestive of cervical spina bifida.

A large membrane-covered anterior thoracoabdominal wall defect was identified. The fetal heart was visualized outside the thoracic cavity, consistent with ectopia cordis. Herniation of the liver, gallbladder, stomach, and bowel loops into the omphalocele sac was noted. The umbilical cord inserted at the apex of the herniated sac. The combination of ectopia cordis and giant omphalocele strongly suggested probable Pentalogy of Cantrell (Toyama Class II).



Figure 1: USG

Postnatal Radiographic Findings (Figure 2)

Infantogram performed following delivery demonstrated complete absence of the cranial vault with exposed malformed brain tissue, confirming acrania. A defect involving the posterior elements of the cervical vertebrae confirmed cervical spina bifida. A large right-sided soft tissue opacity represented the giant omphalocele identified prenatally. The radiographic findings correlated well with the prenatal ultrasound diagnosis.

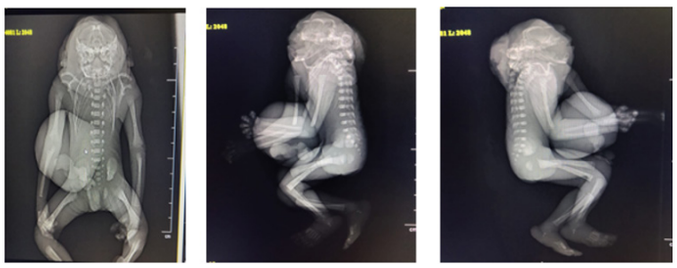

Figure 2: Postnatal Radiographic Findings



Figure 3: X-ray infantogram

DISCUSSION

Pentalogy of Cantrell represents a spectrum of ventral midline developmental defects resulting from abnormal migration of the lateral mesoderm during early embryogenesis. Although complete expression is uncommon, incomplete and probable variants are increasingly recognized because of improvements in prenatal imaging.[1,3] The reported incidence ranges from approximately 1 in 65000 to 1 in 200,000 live births, with a slight male predominance.[3]

The syndrome is diagnosed when characteristic thoracoabdominal abnormalities are identified. The hallmark imaging findings include ectopia cordis and a supraumbilical omphalocele, which should prompt careful evaluation for associated sternal, diaphragmatic, pericardial & intracardiac abnormalities.

According to the Toyama classification, the syndrome is divided into complete (Class I), probable (Class II), and incomplete (Class III) forms. Although direct visualization of diaphragmatic and pericardial defects was limited in the present case, the coexistence of ectopia cordis and giant omphalocele strongly supports a probable diagnosis of Pentalogy of Cantrell.[3]

Neural tube defects associated with Pentalogy of Cantrell are distinctly uncommon. The presence of acrania–anencephaly sequence and cervical spina bifida in our fetus suggests a broader disturbance of early embryogenesis involving both ventral mesodermal and neural tube development.[3]

Ultrasonography remains the primary modality for prenatal diagnosis & may establish the diagnosis as early as the first trimester. Recognition of the frog-eye sign, ectopia cordis, giant omphalocele, and spinal dysraphism permits confident prenatal diagnosis. Postnatal radiography is valuable for confirming skeletal abnormalities.[6,7]

The differential diagnosis includes body stalk anomaly, limb-body wall complex, isolated ectopia cordis, isolated

omphalocele, and amniotic band sequence. Demonstration of ectopia cordis with membrane-covered omphalocele and characteristic thoracoabdominal defects favours Pentalogy of Cantrell.[3,5]

The prognosis is generally poor, particularly in the presence of severe associated neural tube defects. Early prenatal diagnosis allows comprehensive counseling regarding fetal prognosis and pregnancy management.[4]

CONCLUSION

This case illustrates the rare association of probable Pentalogy of Cantrell with acrania–anencephaly sequence and cervical spina bifida. Recognition of the characteristic prenatal imaging findings is essential for timely diagnosis and counselling. Whenever ectopia cordis and omphalocele are encountered, a systematic search for associated thoracoabdominal and central nervous system anomalies should be undertaken.

REFERENCES

1. Cantrell JR, Haller JA, Ravitch MM. A syndrome of congenital defects involving the abdominal wall, sternum, diaphragm, pericardium, and heart. Surg Gynecol Obstet. 1958;107:602-14.
2. Toyama WM. Combined congenital defects of the anterior abdominal wall, sternum, diaphragm, pericardium, and heart: a case report and review of the syndrome. Pediatrics. 1972;50(5):778-92.
3. Carmi R, Boughman JA. Pentalogy of Cantrell and associated midline anomalies: a possible ventral midline developmental field. Am J Med Genet. 1992;42(1):90-5.
4. Hornberger LK, Colan SD, Lock JE, Wessel DL, Mayer JE Jr. Outcome of patients with ectopia cordis and significant intracardiac defects. Circulation. 1996;94(9 Suppl):II32-7.
5. Morales JM, Patel SG, Duff JA, Villareal RL, Simpson JW. Ectopia cordis and other midline defects. Ann Thorac Surg. 2000;70(1):111-4.
6. Desselle C, Hervé P, Toutain A, Lardy H, Sembely C, Perrotin F. Pentalogy of Cantrell: sonographic assessment. J Clin Ultrasound. 2007;35(4):216-20.
7. Rodgers EB, Monteagudo A, Santos R, Greco A, Timor-Tritsch IE. Diagnosis of pentalogy of Cantrell using 2- and 3-dimensional sonography. J Ultrasound Med. 2010;29(12):1825-8.
8. Chandran S, Ari D. Pentalogy of Cantrell: an extremely rare congenital anomaly. J Clin Neonatol. 2013;2(2):95-7.
9. Williams AP, Marayati R, Beierle EA. Pentalogy of Cantrell. Semin Pediatr Surg. 2019;28(2):106-10.

© The Author(s). 2026 Open Access. This article is distributed under the terms of the Creative Commons Attribution 4.0 International License (https://creativecommons.org/licenses/by-nc/4.0/), which permits unrestricted use, distribution, and non-commercial reproduction in any medium, provided you give appropriate credit to the original author(s) and the source, provide a link to the Creative Commons license, and indicate if changes were made. The Creative Commons Public Domain Dedication waiver (http://creativecommons.org/publicdomain/ zero/1.0/) applies to the data made available in this article, unless otherwise stated.