ORIGINAL ARTICLE

Role of Ultrasound in Evaluation of Pelvic Pain: A Cross-Sectional Study

Nikita Gaba[1], Priyanka Goyal[2], Adish Rathi[3]

Rohilkhand Medical College and Hospital, India

Corresponding author:
Nikita Gaba
Rohilkhand Medical College and Hospital, India
Email: nikitagaba18@gmail.com

Received: 25.01.2026
Accepted: 07.02.2026

How to cite this article:
Gaba N, Goyal P, Rathi A. Role of Ultrasound in Evaluation of Pelvic Pain: A Cross-Sectional Study. Int J Adv Integ Med Sci 2026;11(1):22-25.

Source of Support: Nil,
Conflicts of Interest: None declared.

ABSTRACT

Background: Pelvic pain is a frequent and diagnostically challenging presentation in women, spanning gynaecological, obstetrical, urological, and gastrointestinal causes. Ultrasound is endorsed as the first-line imaging modality due to its safety, real-time capability, and cost-effectiveness.

Objectives: To evaluate the role of ultrasonography in assessing the underlying causes of pelvic pain and to identify the spectrum of sonographic findings in female patients at a tertiary care centre.

Methods: A prospective cross-sectional observational study conducted over one year. Eighty female patients with pelvic pain underwent standardized transabdominal and transvaginal ultrasonography with Doppler evaluation where indicated.

Results: Gynaecological causes were most common (73.75%), followed by obstetrical (17.5%) and non-gynaecological causes (8.75%). Ovarian lesions were most frequent (47.46%), with hemorrhagic cysts being the single most common diagnosis (15%). Fibroids predominated among uterine causes (50%). RPOC was the most common obstetrical finding.

Conclusion: Ultrasonography provides high diagnostic yield across the spectrum of pelvic pain etiologies. It is a reliable, safe, and cost-effective first-line imaging tool. Colour Doppler adds functional value in torsion, inflammation, and RPOC. MRI and CT serve as complementary tools in complex cases.

KEYWORDS: pelvic pain, ultrasonography, transvaginal sonography, Doppler, gynaecological pathology, ovarian cyst, fibroid, ectopic pregnancy

INTRODUCTION

Pelvic pain is among the most frequent and diagnostically challenging presentations in gynaecological, radiological, and emergency settings. Its differential diagnosis spans disorders of the reproductive, urinary, gastrointestinal, and musculoskeletal systems, and the overlapping symptoms and shared anatomical spaces make clinical diagnosis alone unreliable.[1,2]

Clinical presentations range from acute pelvic pain — sudden and severe, often requiring urgent evaluation — to chronic pelvic pain (non-cyclic pain lasting ≥6 months). Acute cases commonly raise concern for ectopic pregnancy, adnexal torsion, ruptured hemorrhagic ovarian cyst, or tubo-ovarian abscess. Chronic pain frequently reflects endometriosis, adenomyosis, uterine fibroids, or adhesions.[3,6]

Ultrasound — both transabdominal (TAS) and transvaginal (TVS) — is endorsed as the first-line imaging modality for pelvic pain in reproductive-age women. It is rapid, widely available, free of ionizing radiation, cost-effective, and capable of real-time assessment including Doppler flow analysis.[1-4,7] Transvaginal sonography offers superior spatial resolution for uterine and adnexal structures, while Doppler provides key functional information: absent ovarian flow suggests torsion; increased flow and hyperemia suggest inflammatory or neoplastic processes.[8-11]

CT is reserved for suspected non-gynaecological causes such as appendicitis or urinary calculi. MRI serves as a second-line tool for complex adnexal masses or deep infiltrating endometriosis. Multiple studies confirm that ultrasound alone yields a definitive or highly suggestive diagnosis in the majority of women with pelvic pain.[1,2,9] The present study evaluates the diagnostic role and

spectrum of ultrasonographic findings in female patients at a tertiary care institution.

AIM AND OBJECTIVES

Aim

To evaluate the role of ultrasonography in assessing the underlying causes of pelvic pain in female patients.

Objectives

- To study and identify sonographic features of various pathologies presenting with pelvic pain.
- To analyze the frequency distribution of gynaecological, obstetrical, and non-gynaecological causes as detected on ultrasonography.

MATERIAL AND METHODS

Study Design and Setting

This was a prospective cross-sectional observational study conducted over one year in the Department of Radiodiagnosis, Rohilkhand Medical College and Hospital (RMCH), Bareilly, India. The study was approved by the Institutional Ethics Committee, and written informed consent was obtained from all participants.

Participants

Eighty female patients presenting with pelvic pain and referred for ultrasonographic evaluation were enrolled. Sample size was calculated using the formula $N = 4pq/L^2$, based on a prevalence of 5.2% and allowable error of 5%. Patients with abdominopelvic trauma or hemodynamic instability were excluded.

Ultrasound Protocol

All examinations used a high-resolution ultrasound machine with curvilinear transabdominal probes (3.5–5 MHz) and transvaginal probes (5–12 MHz). TAS was performed with a distended bladder; TVS in non-virginal consenting patients with an emptied bladder. Colour and spectral Doppler were applied where vascular assessment was indicated.

Statistical Analysis

Data were analyzed using SPSS version 23.0. Quantitative variables are expressed as mean ± SD; qualitative variables as frequency and percentage. A p-value of <0.05 was considered statistically significant.

RESULTS

A total of 80 female patients presenting with pelvic pain were enrolled. The complete spectrum of sonographic diagnoses is presented in Table 1.

Table 1: Distribution of all sonographic diagnoses in pelvic pain (N=80)

Diagnosis	Cases (N=80)	Percentage (%)
Fibroid	9	11.25
Adenomyosis	5	6.25
Endometrial Polyp	3	3.75
Asherman Syndrome	1	1.25
Cervical Polyp	3	3.75
Cervical Fibroid	1	1.25
Cervical Neoplasm	2	2.50
Hemorrhagic Cyst	12	15.00
Endometrioma	6	7.50
Dermoid Cyst	4	5.00
Cystadenoma	3	3.75
ORADS 4/5	2	2.50
Ovarian Torsion	1	1.25
Hydrosalpinx	5	6.25
Pyosalpinx	2	2.50
Ectopic Pregnancy	4	5.00
RPOC	7	8.75
GTD	2	2.50
Abruptio Placenta	1	1.25
Cystitis	4	5.00
Appendicitis	2	2.50
Vesical Calculus	1	1.25

Etiological Distribution

Gynaecological causes constituted the majority at 73.75% (n=59), followed by obstetrical causes at 17.5% (n=14), and non-gynaecological causes at 8.75% (n=7) (Table 2).

Table 2: Etiological distribution of pelvic pain (N=80)

Etiology	Cases	Percentage (%)
Gynaecological	59	73.75
Obstetrical	14	17.50
Non-Gynaecological / Non-Obstetrical	7	8.75

Gynaecological Causes by Organ

Among the 59 gynaecological cases, ovarian pathologies were most frequent at 47.46% (n=28), followed by uterine (30.51%, n=18), tubal (11.86%, n=7), and cervical (10.17%, n=6) causes (Table 3).

Table 3: Organ-wise distribution of gynaecological causes (N=59)

Organ Involved	Cases (N=59)	Percentage (%)
Ovarian	28	47.46
Uterine	18	30.51
Tubal	7	11.86
Cervical	6	10.17

Uterine and Ovarian Pathologies

Uterine fibroids were the most common uterine lesion (50%), followed by adenomyosis (27.78%), endometrial polyp (16.67%), and Asherman syndrome (5.56%). Among fibroids, intramural type predominated (66.67%). Tables 4 and 5 detail uterine pathology and fibroid sub-types.

Table 4: Types of uterine pathologies (N=18)

Diagnosis	N	%
Fibroid	9	50.00
Adenomyosis	5	27.78
Endometrial Polyp	3	16.67
Asherman Syndrome	1	5.56

Table 5: Types of uterine fibroids (N=9)

Fibroid Type	N	%
Intramural	6	66.67
Subserosal	2	22.22
Submucosal	1	11.11

Hemorrhagic cysts were the most common ovarian lesion (42.86%), followed by endometriomas (21.43%), dermoid cysts (14.29%), cystadenomas (10.71%), ORADS 4/5 lesions (7.14%), and torsion (3.57%) (Table 6).

Table 6: Types of ovarian pathologies (N=28)

Diagnosis	Cases (N=28)	Percentage (%)
Hemorrhagic Cyst	12	42.86
Endometrioma	6	21.43
Dermoid Cyst	4	14.29
Cystadenoma	3	10.71
ORADS 4/5	2	7.14
Torsion	1	3.57

Tubal, Obstetrical, and Non-Gynaecological Causes

Among tubal causes, hydrosalpinx was predominant (71.43%) over pyosalpinx (28.57%). Cervical polyps accounted for 50% of cervical lesions. Obstetrical causes were led by RPOC (50%), followed by ectopic pregnancy (28.57%), GTD (14.29%), and abruptio placentae (7.14%). Among non-gynaecological causes, cystitis was most frequent (57.14%), followed by vesical calculus (28.57%) and appendicitis (14.29%).

DISCUSSION

This study highlights the pivotal role of ultrasonography in evaluating female patients with pelvic pain. Gynaecological causes dominated at 73.75%, followed by obstetrical (17.5%) and non-gynaecological causes (8.75%) — a distribution consistent with published literature reporting gynaecological etiologies in approximately 70–80% of women undergoing pelvic ultrasound for pain evaluation.

Hemorrhagic ovarian cysts were the single most common diagnosis (15% of all cases), reflecting physiological ovulatory changes and the ease with which ultrasound detects the classic reticular 'fishnet' internal echogenicity. Uterine fibroids emerged as the most common uterine pathology (50%), with intramural fibroids predominating (66.67%), consistent with their known association with pelvic pressure and degenerative pain. Adenomyosis was identified in 27.78% of uterine cases using TVS criteria, supporting data that modern TVS achieves diagnostic accuracy comparable to MRI for this condition.

Among obstetrical causes, RPOC constituted 50% of cases, reliably detected using endometrial thickness and Doppler vascularity criteria. Ectopic pregnancy (28.57%) was identified via TVS with high sensitivity, consistent with published reports of >90% sensitivity. Non-gynaecological causes (8.75%) — including cystitis, vesical calculi, and appendicitis — were identified during routine scanning, reinforcing the value of a comprehensive scanning approach. Colour Doppler added significant value for ovarian torsion, inflammatory lesions, and RPOC.

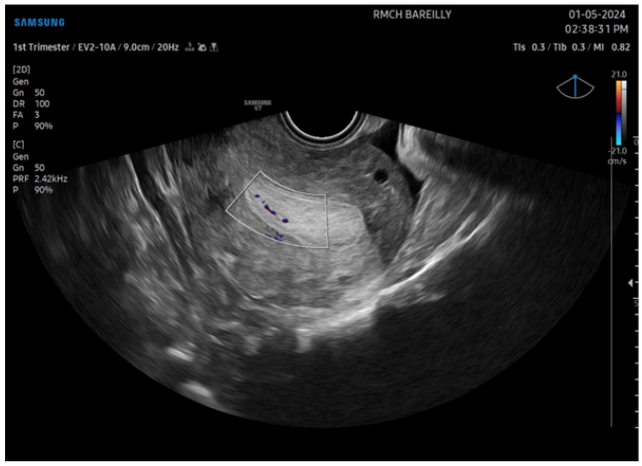

Figure 1: Endometrial Polyp — Echogenic lesion with vascular stalk on Colour Doppler (TVS, RMCH Bareilly).

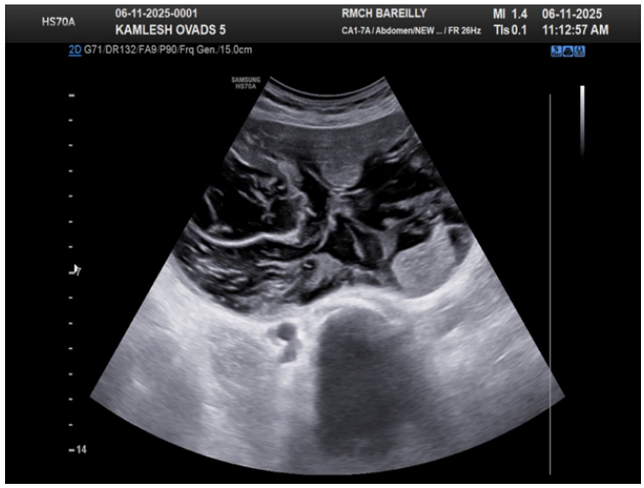

Figure 2: ORADS 5 Ovarian Mass — Large solid-cystic mass with thick septations and vascularity on Doppler (TAS, RMCH Bareilly).

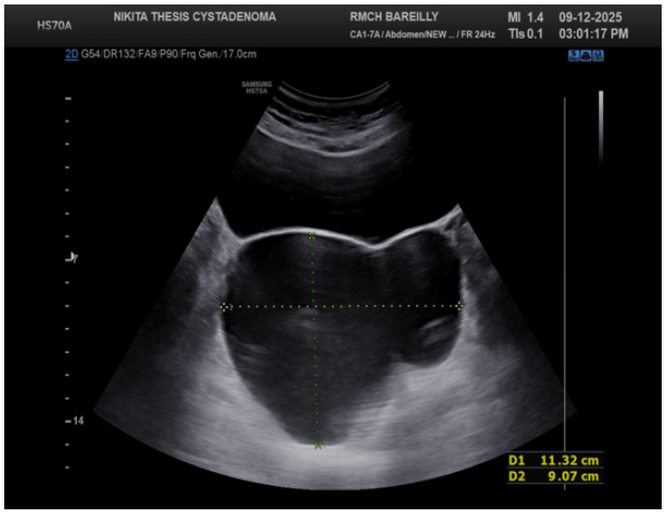

Figure 3: Serous Cystadenoma — Large unilocular anechoic cyst with thin septations, right ovary; D1: 11.32 cm (TAS, RMCH Bareilly).

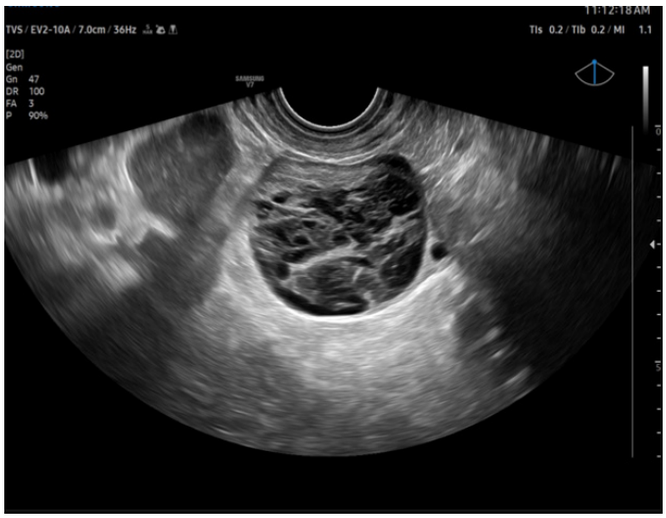

Figure 4: Hemorrhagic Ovarian Cyst — Cystic lesion with internal septations and echoes, right ovary (TVS, RMCH Bareilly).

CONCLUSION

Ultrasonography is a reliable, efficient, and indispensable first-line imaging modality for the evaluation of pelvic pain in women. It provides high diagnostic yield across a broad spectrum of gynaecological, obstetrical, and non-gynaecological pathologies. Gynaecological causes predominated, with hemorrhagic ovarian cysts as the most common finding. Colour Doppler augmented diagnostic confidence in vascular and inflammatory conditions. MRI and CT serve as complementary tools in complex cases, but the safety, accessibility, real-time capability, and cost-effectiveness of ultrasound firmly establish it as the investigation of first choice. Larger multicentric studies incorporating histopathological correlation are recommended to validate and extend these findings.

REFERENCES

1. Amirbekian S, Hooley RJ. Ultrasound evaluation of pelvic pain. Radiol Clin North Am. 2014;52(6):1215-35.
2. Nikolic MB, Basta Nikolic M, Vojvodic D. Imaging of acute pelvic pain. BJR Open. 2021;3(1):20210006.
3. Brook OR, et al. ACR Appropriateness Criteria® acute pelvic pain in the reproductive age group. J Am Coll Radiol. 2024;21(4):516-24.
4. Cicchiello LA, Hamper UM, Scoutt LM. Ultrasound evaluation of gynecologic causes of pelvic pain. Obstet Gynecol Clin North Am. 2011;38(1):85-114.
5. Kruszka PS, Kruszka SJ. Evaluation of acute pelvic pain in women. Am Fam Physician. 2010;82(2):141-7.
6. Masselli G, et al. Imaging for acute pelvic pain in pregnancy. Insights Imaging. 2014;5:165-81.
7. Andreotti RF, Harvey SM. Sonographic evaluation of acute pelvic pain. J Ultrasound Med. 2012;31(11):1713-8.
8. Rostamzadeh A, et al. Diagnostic efficacy of sonography in ovarian torsion: a systematic review. J Clin Ultrasound. 2014;42(7). [Page numbers required].
9. Talat H, et al. Sonographic findings of gynaecological causes of acute pelvic pain. J Ultrason. 2022;22(90):e183-90.
10. Wang XH, et al. Impact of ultrasound diagnosis for chronic pelvic pain. Medicine (Baltimore). 2019;98(27):e16371.
11. Garde I, et al. Diagnostic accuracy of ultrasound signs for detecting adnexal torsion. Ultrasound Obstet Gynecol. 2023; 61(3):310–24

© The Author(s). 2026 Open Access. This article is distributed under the terms of the Creative Commons Attribution 4.0 International License (https://creativecommons.org/licenses/by-nc/4.0/), which permits unrestricted use, distribution, and non-commercial reproduction in any medium, provided you give appropriate credit to the original author(s) and the source, provide a link to the Creative Commons license, and indicate if changes were made. The Creative Commons Public Domain Dedication waiver (http://creativecommons.org/publicdomain/ zero/1.0/) applies to the data made available in this article, unless otherwise stated.