Original Article

Role of High-Resolution Computed Tomography in Patients with Pulmonary Tuberculosis

Adish Rathi[1], Harsh Kumar[2], Nikita Gaba[3]

Rohilkhand Medical College and Hospital, Bareilly, Uttar Pradesh, India

Corresponding author:
Adish Rathi
Rohilkhand Medical College and Hospital, India
Email: adishrathi1997@gmail.com

Received: 02.02.2026
Accepted: 15.02.2026

How to cite this article:
Rathi A, Kumar H, Gaba N. Role of High-Resolution Computed Tomography in Patients with Pulmonary Tuberculosis. Int J Adv Integ Med Sci 2026;11(1):18-21.

Source of Support: Nil,
Conflicts of Interest: None declared.

ABSTRACT

Background: Pulmonary tuberculosis (PTB) remains a major public health burden in developing countries. Early diagnosis and differentiation between active and inactive disease are essential for timely treatment and prevention of transmission. HRCT provides detailed evaluation of pulmonary parenchymal abnormalities and may detect disease activity more accurately than conventional radiography.

Objectives: To evaluate the role of HRCT in pulmonary tuberculosis, identify characteristic imaging patterns, and correlate HRCT findings with laboratory-confirmed disease activity.

Methods: A cross-sectional study was conducted in the Department of Radio-diagnosis, Rohilkhand Medical College and Hospital, Bareilly, over one year. A total of 120 clinically suspected or laboratory-confirmed pulmonary tuberculosis patients underwent HRCT chest examination. HRCT findings were compared with sputum smear and CB-NAAT/TRU-NAAT results. Statistical analysis was performed using SPSS version 23.0. A p-value <0.05 was considered statistically significant.

Results: The mean age was 44.84 ± 17.73 years; males comprised 60.83%. Active PTB was diagnosed in 72 (60%) patients and inactive disease in 48 (40%). Centrilobular nodules (83.33% vs 12.5%; p=0.0001), tree-in-bud pattern (70.84% vs 18.75%; p=0.003), consolidation (66.67% vs 18.75%; p=0.004), and cavitation (66.67% vs 25%; p=0.022) were significantly associated with active disease. Fibrosis (81.25% vs 33.33%; p=0.008) and traction bronchiectasis (68.75% vs 29.16%; p=0.023) were significantly associated with inactive disease.

Conclusion: HRCT is a valuable imaging modality for evaluating pulmonary tuberculosis and differentiating active from inactive disease. Centrilobular nodules, tree-in-bud pattern, consolidation, and cavitation are reliable indicators of active tuberculosis, while fibrosis and traction bronchiectatic changes suggest inactive disease.

KEYWORDS: Pulmonary tuberculosis, HRCT, active tuberculosis, tree-in-bud pattern, centrilobular nodules, cavitation

INTRODUCTION

Tuberculosis (TB) continues to be a major cause of morbidity and mortality worldwide, particularly in developing countries such as India. Despite advances in diagnostic techniques and implementation of the National Tuberculosis Elimination Programme (NTEP), pulmonary tuberculosis remains a significant healthcare challenge.[1,2]

Diagnosis of pulmonary tuberculosis traditionally relies on clinical evaluation, chest radiography, sputum smear microscopy, culture, and nucleic acid amplification tests. However, chest radiographs may be inconclusive and microbiological confirmation may be delayed, especially in smear-negative patients.[1,3]

HRCT has emerged as an important imaging modality because of its superior spatial resolution and ability to detect subtle parenchymal abnormalities. HRCT can identify early manifestations of pulmonary tuberculosis, assess disease extent, distinguish active from inactive lesions, and evaluate complications.[3-6]

The present study was conducted to evaluate the role of HRCT in pulmonary tuberculosis and determine imaging findings associated with disease activity.

MATERIALS AND METHODS

Study Design and Setting

A cross-sectional observational study was conducted in the Department of Radiodiagnosis, Rohilkhand Medical College and Hospital, Bareilly, Uttar Pradesh, India, over a period of one year.

Sample Size and Participants

A total of 120 patients were included. Sample size was calculated using the formula $n = 4pq/L^2$, based on prevalence data from a previous study.[7]

Inclusion Criteria:

- Clinically suspected pulmonary tuberculosis
- Patients diagnosed with pulmonary tuberculosis by sputum smear, CB-NAAT, or TRU-NAAT

Exclusion Criteria:

- Pregnant women
- Patients with known malignancy

HRCT Protocol

HRCT chest was performed on a 16-slice CT scanner with patients in the supine position during full inspiration. Parameters: tube voltage 120 kVp; tube current 100–200 mAs; slice thickness 0.625–1.25 mm; reconstruction interval 0.625 mm.

Imaging Findings Evaluated

The following HRCT findings were recorded and analyzed: centrilobular nodules, tree-in-bud pattern, consolidation, cavitation, ground-glass opacity, mediastinal lymphadenopathy, fibrosis, traction bronchiectasis, emphysema, pleural effusion, calcified granuloma, and pleural thickening.

Statistical Analysis

Data were analyzed using SPSS version 23.0. Descriptive statistics were expressed as frequencies and percentages. Fisher's exact test was applied where appropriate. A p-value <0.05 was considered statistically significant.

RESULTS

Demographic Characteristics

Among 120 patients, the mean age was 44.84 ± 17.73 years. The largest age group was 48–57 years (24.17%). Male patients constituted 73 (60.83%) of cases and females 47 (39.17%). Active pulmonary tuberculosis was present in 72 (60%) patients, while 48 (40%) had inactive disease.

Frequency of HRCT Findings

Table 1 summarizes the frequency of all HRCT findings in the study population.

Table 1: Frequency of HRCT Findings in 120 Patients with Pulmonary Tuberculosis

HRCT Finding	Frequency (%)
Centrilobular nodules	55.0
Fibrosis	52.5
Tree-in-bud pattern	50.0
Cavitation	50.0
Consolidation	47.5
Traction bronchiectasis	45.0
Mediastinal lymphadenopathy	37.5
Emphysema	37.5
Calcified granuloma	32.5
Ground-glass opacity	30.0
Pleural effusion	30.0

HRCT Findings and Disease Activity

Tables 2 and 3 compare HRCT findings between active and inactive disease groups. Centrilobular nodules, tree-in-bud pattern, consolidation, and cavitation were significantly more prevalent in active tuberculosis. Fibrosis and traction bronchiectasis were significantly associated with inactive disease.

Table 2: HRCT Findings Significantly Associated with Active Pulmonary Tuberculosis

HRCT Finding	Active TB (%)	Inactive TB (%)	p-value
Centrilobular nodules	83.33	12.50	<0.001
Tree-in-bud pattern	70.84	18.75	0.003
Consolidation	66.67	18.75	0.004
Cavitation	66.67	25.00	0.022

Table 3: HRCT Findings Significantly Associated with Inactive Pulmonary Tuberculosis

HRCT Finding	Active TB (%)	Inactive TB (%)	p-value
Fibrosis	33.33	81.25	0.008
Traction bronchiectasis	29.16	68.75	0.023

Ground-glass opacity, mediastinal lymphadenopathy, emphysema, pleural effusion, calcified granuloma, and pleural thickening did not show a statistically significant association with disease activity.

DISCUSSION

HRCT demonstrated significant utility in differentiating active from inactive pulmonary tuberculosis. The most frequent findings associated with active disease were centrilobular nodules, tree-in-bud appearance, consolidation, and cavitation.[5-10]

Centrilobular nodules were observed in 83.33% of active cases and showed the strongest association with disease activity ($p<0.001$). This finding is consistent with previous reports by Hatipoğlu et al., Tozkoparan et al., and Ors et al., which identified centrilobular nodules as hallmark features of active pulmonary tuberculosis.[6,7,9]

The tree-in-bud pattern, representing endobronchial spread of infection, was significantly more prevalent in active disease (70.84% vs 18.75%; $p=0.003$). Similar observations have been reported by Raniga et al. and Hatipoğlu et al.[6,8]

Consolidation and cavitation also demonstrated significant associations with active pulmonary tuberculosis. Cavitary lesions indicate a high bacillary burden and have been linked with increased infectivity and transmission risk.[5,10,11]

In contrast, fibrosis and traction bronchiectasis were significantly associated with inactive disease, reflecting chronic structural sequelae following healed infection. These findings are consistent with prior literature describing fibrotic changes as markers of inactive pulmonary tuberculosis.[12]

The present study highlights the importance of HRCT in clinical scenarios where chest radiography is inconclusive or microbiological confirmation is delayed, particularly in smear-negative cases.[5,7,8]

Limitations

- Single-centre study with a relatively small sample size
- Longitudinal treatment response was not assessed
- Culture-based microbiological confirmation was not available for all cases

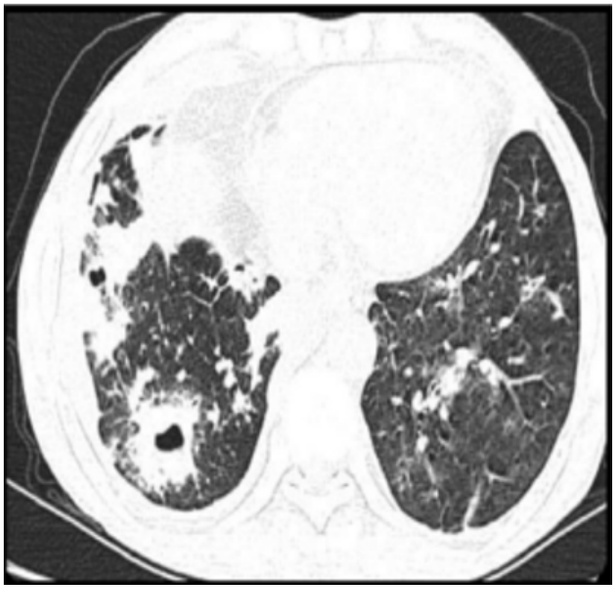

Fig. 1: Consolidation with cavitations in right lower lobe (active TB)



Fig. 2: Fibrobronchiectasis in bilateral lung parenchyma (inactive TB)



Fig. 3: Marked fibrosis with architectural distortion, bilateral upper lobes (inactive TB)

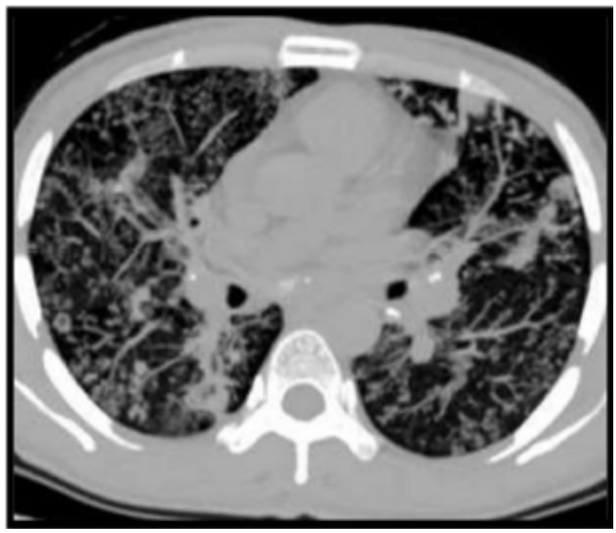

Fig. 4: Centrilobular nodules forming tree-in-bud pattern, bilateral (active 7B)

CONCLUSION

HRCT plays a pivotal role in the evaluation of pulmonary tuberculosis and is highly effective in distinguishing active from inactive disease. Centrilobular nodules, tree-in-bud pattern, consolidation, and cavitation are significant imaging indicators of active pulmonary tuberculosis. Fibrosis and traction bronchiectasis are reliable markers of inactive disease.[5,10]

HRCT should be considered an important adjunct to microbiological investigations, particularly in clinically suspected cases with equivocal radiographic findings or delayed laboratory confirmation.

REFERENCES

1. World Health Organization. Global tuberculosis report 2023. Geneva: World Health Organization; 2023.
2. Central TB Division. India TB report 2023. New Delhi: Ministry of Health and Family Welfare, Government of India; 2023.
3. Im JG, Itoh H, Shim YS, et al. Pulmonary tuberculosis: CT findings—early active disease and sequential change with antituberculous therapy. Radiology. 1993;186(3):653-60.
4. Lee KS, Song KS, Lim TH, et al. Adult-onset pulmonary tuberculosis: findings on chest radiographs and CT scans. AJR Am J Roentgenol. 1993;160(4):753-8.
5. Jeong YJ, Lee KS. Pulmonary tuberculosis: up-to-date imaging and management. AJR Am J Roentgenol. 2008;191(3):834-44.
6. Hatipoğlu ON, Osma E, Manisali M, et al. High-resolution computed tomographic findings in pulmonary tuberculosis. Thorax. 1996;51(4):397-402.
7. Tozkoparan E, Deniz O, Ciftci F, et al. The roles of HRCT in diagnosing active pulmonary tuberculosis. Tuberk Toraks. 2005;53(1):19-27.
8. Raniga S, Parikh N, Arora A, Vaghani M. Is HRCT reliable in determining disease activity in pulmonary tuberculosis? Indian J Radiol Imaging. 2006;16(2):221-8.
9. Ors F, Deniz O, Bozlar U, et al. High-resolution CT findings in patients with pulmonary tuberculosis. Eur J Radiol. 2007;61(3):555-60.
10. Burrill J, Williams CJ, Bain G, et al. Tuberculosis: a radiologic review. Radiographics. 2007;27(5):1255-73.
11. Woodring JH, Vandiviere HM, Fried AM, et al. Update: the radiographic features of pulmonary tuberculosis. AJR Am J Roentgenol. 1986;146(3):497-506.
12. Kim HY, Song KS, Goo JM, et al. Thoracic sequelae and complications of tuberculosis. Radiographics. 2001;21(4):839-58.

© The Author(s). 2026 Open Access. This article is distributed under the terms of the Creative Commons Attribution 4.0 International License (https://creativecommons.org/licenses/by-nc/4.0/), which permits unrestricted use, distribution, and non-commercial reproduction in any medium, provided you give appropriate credit to the original author(s) and the source, provide a link to the Creative Commons license, and indicate if changes were made. The Creative Commons Public Domain Dedication waiver (http://creativecommons.org/publicdomain/ zero/1.0/) applies to the data made available in this article, unless otherwise stated.