ORIGINAL ARTICLE

Role of Multidetector Computed Tomography Scan in the Assessment of Mediastinal and Hilar Masses: A Cross-Sectional Study

Saras Mittal[1], Kriti Gupta[2]

[1,2]*Junior resident, Department of Radiodiagnosis, Rohilkhand Medical College and Hospital, Bareilly, Uttar Pradesh, India*

Corresponding author:
Saras Mittal, Junior resident
Department of Radiodiagnosis, Rohilkhand Medical College and Hospital, Bareilly, Uttar Pradesh, India
Email: Sarasmittal9090@gmail.com

Received: 08.03.2026
Accepted: 01.04.2026

How to cite this article:
Mittal S, Gupta K.
Role of Multidetector Computed Tomography Scan in the Assessment of Mediastinal and Hilar Masses: A Cross-Sectional Study. Int J Adv Integ Med Sci 2026;11(1):6-10.
Source of Support: Nil,
Conflicts of Interest: None declared.

ABSTRACT

Introduction: Mediastinal and hilar masses encompass diverse benign and malignant conditions with limited characterization on chest radiography. Multidetector computed tomography (MDCT) enables accurate localization, tissue characterization, and assessment of disease extent.

Objectives: To assess the efficacy of MDCT in evaluating mediastinal and hilar masses, their compartmental distribution, and CT characteristics on plain and contrast studies.

Methods: This cross-sectional study included 62 patients with suspected mediastinal or hilar masses evaluated over one year. All underwent plain and contrast-enhanced MDCT. Lesion location, attenuation, enhancement, and associated findings were analyzed. Statistical analysis was performed using SPSS v25.

Results: Anterior mediastinal involvement was most common (43.5%), followed by posterior (33.8%) and middle (22.5%) compartments. Lymphoma was the predominant diagnosis (35.4%). Malignant lesions marginally exceeded benign lesions (48.4% vs 43.5%), with a significant association between lesion type and compartment ($p = 0.007$). Hypodense lesions were most frequent (56.7%), and moderate enhancement was the dominant pattern (51.6%), particularly in malignant masses.

Conclusion: MDCT is a reliable modality for comprehensive evaluation of mediastinal and hilar masses, facilitating accurate localization, characterization, and differentiation of lesions, and aiding appropriate clinical management.

Keywords: Multidetector CT, Mediastinal masses, Hilar masses, Contrast-enhanced CT, Thoracic imaging

INTRODUCTION

The mediastinum is an anatomically complex region containing vital structures such as the heart, great vessels, tracheobronchial tree, esophagus, thymus, lymphatic tissue, and major neurovascular bundles. Owing to this structural diversity, mediastinal and hilar masses constitute a heterogeneous group of lesions, and accurate compartmental localization is fundamental for narrowing differential diagnoses. A standardized mediastinal compartment classification improves diagnostic accuracy and facilitates effective multidisciplinary communication in clinical practice.[1] Radiological evaluation is therefore central to the initial assessment of these lesions.[2]

Mediastinal and hilar masses include a wide range of benign and malignant conditions such as thymic lesions, lymphomas, germ cell tumors, neurogenic tumors, metastatic lymphadenopathy, and granulomatous diseases. These lesions affect all age groups and often present with nonspecific clinical features or are detected incidentally, making imaging a critical diagnostic tool.[3] The overlapping clinical and radiological presentations pose diagnostic challenges, emphasizing the need for advanced cross-sectional imaging techniques.[4]

Clinically, early and accurate characterization of mediastinal masses directly influences patient management by guiding biopsy decisions, surgical planning, oncologic treatment, or conservative follow-up.[5] In both global and Indian settings, mediastinal and hilar masses represent a significant diagnostic burden in tertiary care hospitals, particularly due to the prevalence of tuberculosis, lymphoma, and bronchogenic malignancies.[6,7] Conventional radiography has limited diagnostic value, while histopathology, though definitive, is invasive and not always immediately feasible.

Multidetector computed tomography (MDCT) serves as the primary imaging modality for evaluating mediastinal and hilar masses due to its high spatial resolution, multiplanar

capabilities, and superior tissue characterization.[8] MDCT enables precise assessment of lesion location, morphology, internal composition, vascular involvement, and invasion of adjacent structures, thereby improving diagnostic confidence and correlation with pathological findings.[9,10] However, systematic regional evaluations correlating MDCT findings with final diagnoses remain limited, underscoring the need for the present study.

MATERIAL AND METHODS

Study Type: Cross sectional study.

Study Population: All suspected cases of mediastinal and hilar masses came for computed tomography.

Study Setting: Department of Radiodiagnosis, Rohilkhand Medical College.

Study Duration: One year.

Sample Size: 62 cases

Sampling Technique: Simple random sampling method was used to include the sample in the study

Inclusion and Exclusion criteria

Inclusion Criteria:

- Individuals of any gender and age group who are thought to have a mediastinal mass lesion based on clinical evaluation.
- Indication of an enlarged or abnormal growth in the mediastinum on a chest radiograph.

Exclusion Criteria:

- History of hypersensitivity to intravenous contrast agents;
- Deranged renal function (serum creatinine > 1.5 mg/dL).
- Post-surgical patients.
- Pregnant women

Statistical analysis: Data were analyzed using SPSS v25. Continuous variables were mean±SD; categorical variables frequency/percentage. Chi-square tested associations. MDCT diagnostic performance assessed versus histopathology; $p<0.05$ significant, including sensitivity specificity PPV NPV accuracy.

RESULTS

In Figure 1, Among the 62 study participants, the anterior mediastinum was the most commonly involved compartment, accounting for 43.5% of cases, followed by the posterior mediastinum (33.8%) and middle mediastinum (22.5%).

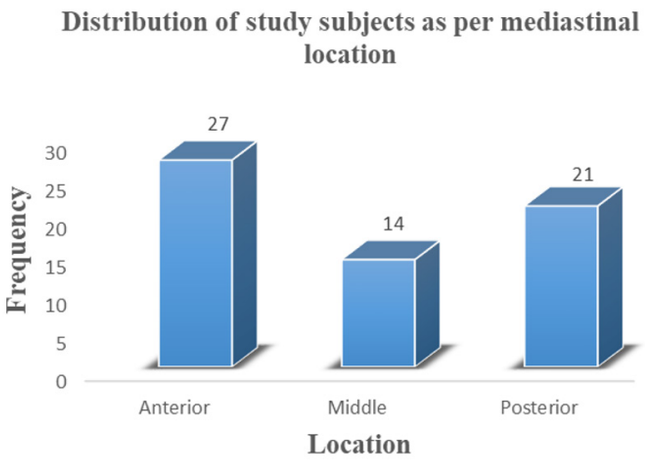

Figure 1: Distribution of study subjects as per mediastinal location

In Figure 2, CT evaluation revealed that lymphoma was the most common mediastinal pathology, accounting for 35.4% of cases, followed by thymoma (17.7%), thymic cyst (8.0%), and sarcoidosis (8.0%). Less frequent findings included bronchogenic cysts (6.4%), mediastinal teratoma (4.8%), thymolipoma (4.8%), malignant neoplasm of the oesophagus (4.8%), and oesophageal duplication cyst (1.6%). The distribution was significant, confirming that neoplastic and cystic lesions comprised the majority of mediastinal and hilar masses. These results demonstrate the high diagnostic yield of multidetector CT (MDCT) in identifying and characterizing various mediastinal pathologies, with lymphoma being the predominant diagnosis.

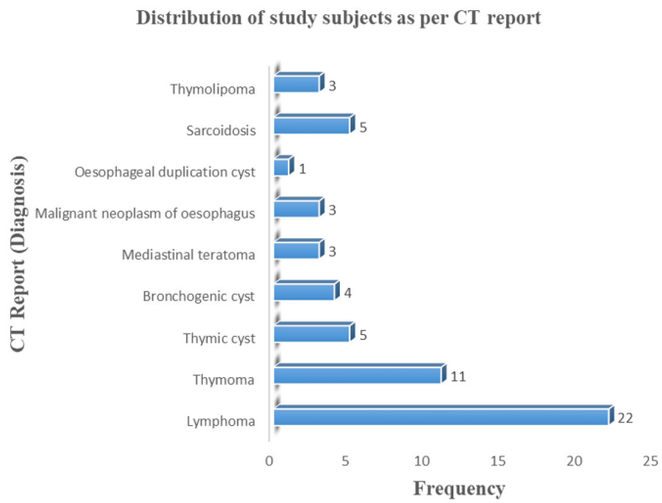

Figure 2: Distribution of study subjects as per CT report

Table 1 Shows, the anterior mediastinum was the most frequently involved compartment (43.5%), followed by the posterior (33.8%) and middle (22.5%) compartments. Among lesion types, malignant masses (48.4%) slightly outnumbered benign lesions (43.5%), while aneurysms (8.1%) were the least common. Notably, malignant lesions

predominated in the posterior mediastinum (20.9%), whereas benign lesions were more common in the anterior compartment (22.5%). The observed association between compartmental location and lesion type was statistically significant (p = 0.007), emphasizing that anterior mediastinal masses are primarily benign or thymic in origin, while posterior masses tend to be malignant or neurogenic.

Table 1: Distribution of Mediastinal Masses by Compartment and Type

Mediastinal Compartment	Benign n (%)	Malignant n (%)	Aneurysm n (%)	Total n (%)	p-value
Anterior	14 (22.5%)	11 (17.7%)	2 (3.2%)	27 (43.5%)	0.007
Middle	6 (9.6%)	6 (9.6%)	2 (3.2%)	14 (22.5%)	
Posterior	7 (11.2%)	13 (20.9%)	1 (1.6%)	20 (33.8%)	
Total	27 (43.5%)	30 (48.4%)	5 (8.1%)	62 (100%)	

In Figure 3, On CT evaluation, the majority of mediastinal masses were hypodense (56.7%), followed by isoattenuating (16.0%), mixed density (12.9%), and hyperdense (12.9%) lesions. The variation among attenuation patterns was significant, suggesting that density characteristics on CT provide valuable clues to the lesion's composition and pathology. Hypodense lesions, often indicative of necrosis, cystic degeneration, or fluid content, were the most prevalent, reflecting the predominance of soft-tissue or necrotic components in mediastinal masses.

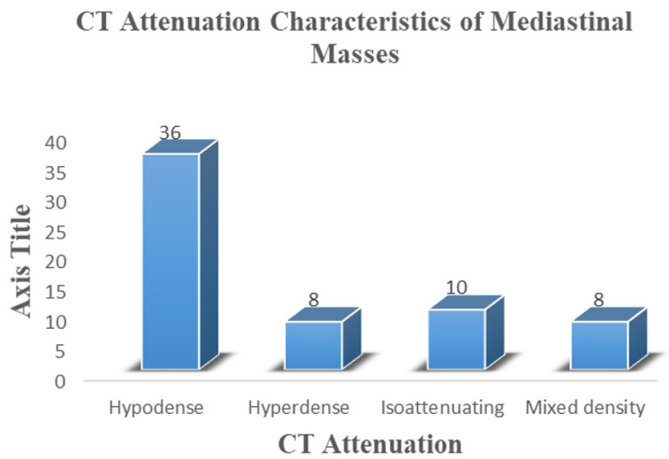

Figure 3: CT Attenuation Characteristics of Mediastinal Masses

Table 2 Shows When enhancement pattern was correlated with lesion type, moderate enhancement was most frequently observed (51.6 %)—predominantly among malignant lesions (29.0 %), followed by benign lesions (20.9 %). Mild enhancement was more common in benign lesions (14.5 %), whereas severe enhancement was observed in both malignant (11.3%) and aneurysmal (3.2%) cases.

Table 2: Correlation of CT Enhancement Pattern with Type of Lesion

Enhancement Pattern	Benign n (%)	Malignant n (%)	Aneurysm n (%)	Total n (%)
Mild	9 (14.5%)	5 (8.0%)	2 (3.2%)	16 (25.8%)
Moderate	13 (20.9%)	18 (29.0%)	1 (1.6%)	32 (51.6%)
Severe	5 (8.1%)	7 (11.3%)	2 (3.2%)	14 (22.5%)
Total	27 (43.5%)	30 (48.4%)	5 (8.1%)	62 (100%)



Figure 4: On saggital CECT scan: A circumscribed heterogeneously enhancing mass lesion in the anterior and middle mediastinum.The lesion is causing complete encasement of arch of aorta and its branches without any luminal compromise.



Figure 5: On axial CECT: An ill-defined irregular spiculated hetrogenously enhancing soft tissue mass lesion in right perihilar region causing cut off of right upper lobe bronchus with collapse of right upper lobe.

DISCUSSION

The present study demonstrated a predominant involvement of the anterior mediastinum (43.5%), followed by the posterior (33.8%) and middle mediastinum (22.5%), a distribution that closely aligns with observations by Gadia et al. (2019)[9] and Singh SS et al. (2019),[10] both of whom reported the anterior mediastinum as the most frequently affected compartment. Similar compartmental predominance was also noted by El Shalakany NM et al. (2021),[11] though their work focused exclusively on posterior mediastinal lesions, reporting a substantial burden of malignant and lymph nodal pathologies in that compartment, which parallels the higher proportion of malignant lesions in the posterior mediastinum (20.9%) observed in the present study. In contrast, Kumar et al. (2021) [12] reported a relatively higher proportion of middle mediastinal lymph nodal lesions, highlighting minor variations attributable to differences in case mix and referral patterns. Lymphoma emerged as the most common pathology in the current study (35.4%), consistent with the predominance of lymphomatous and metastatic lymphadenopathy described by Gadia et al. (2019) [9], Singh SS et al. (2019) [10], and El Shalakany NM et al. (2021) [11], supporting MDCT's reliability in identifying lymphoid malignancies. The statistically significant association between mediastinal compartment and lesion type ($p = 0.007$) further corroborates prior evidence that anterior mediastinal lesions are frequently benign or thymic, whereas posterior lesions are more often malignant or neurogenic, as documented by Gadia et al. (2019) [9] and Kumar et al. (2021) [12], Attenuation analysis revealed hypodense lesions as the most common (56.7%), a finding comparable to prior studies reporting cystic or necrotic components as dominant CT features. Enhancement characteristics in the present study showed moderate enhancement predominating (51.6%), particularly among malignant lesions (29.0%), mirroring enhancement trends described by El Shalakany NM et al. (2021) [11] before Kumar et al. (2021) [12], The distinct documentation of aneurysms (8.1%) and their severe enhancement pattern represents a unique observation, underscoring MDCT's added value in identifying vascular etiologies without necessitating forced comparison.

CONCLUSION

Multidetector CT proved highly effective for evaluating mediastinal and hilar masses by accurately defining compartmental location, spatial extent, internal composition, attenuation characteristics, and enhancement behavior on plain and contrast studies, thereby directly fulfilling the study objectives. In this cohort of 62 patients, anterior mediastinal involvement was most frequent (43.5%), followed by posterior (33.8%) and middle (22.5%) compartments, and lesion distribution showed a significant association between compartment and lesion type ($p = 0.007$), with posterior lesions more often malignant (20.9%) and anterior lesions more often benign/thymic (22.5%). Lymphoma was the leading diagnosis (35.4%), with thymoma (17.7%) and other cystic/neoplastic entities forming the majority spectrum, supporting MDCT's strong diagnostic yield in characterizing diverse mediastinal pathologies. Hypodensity predominated (56.7%), reinforcing the value of attenuation in suggesting cystic or necrotic components, while moderate enhancement (51.6%)—particularly among malignant lesions (29.0%)—further strengthened lesion characterization and triage for histopathological confirmation where required.

REFERENCES

1. Carter BW, Benveniste MF, Madan R, Godoy MCB, de Groot PM, Truong MT, et al. ITMIG classification of mediastinal compartments and multidisciplinary approach to mediastinal masses. Radiographics. 2017;37(2):413-36.
2. Carter BW, Benveniste MF, Marom EM. Diagnostic approach to the anterior/prevascular mediastinum for radiologists. Mediastinum. 2019;3:18.
3. Arumugam V, Nazir H, Rajasekar KV. Multidetector computed tomography evaluation of mediastinal lesions with histopathological diagnosis. Open J Respir Dis. 2015;5(3):55-62.
4. Pandey S, Jaipal U, Mannan N, Yadav R. Diagnostic accuracy of multidetector computed tomography scan in mediastinal masses assuming histopathological findings as gold standard. Pol J Radiol. 2018;83:e234-42.
5. Pulasani K, Narayanaswamy I, Ramprakash HV. Evaluation of mediastinal mass lesions using multi-detector row computed tomography and correlation with histopathological diagnosis. Int J Sci Stud. 2015;3(6):156-63.
6. Shashikumar MR, Rajendra KN, Nanjaraj CP, Kumar CP, Manupratap N, Chandrashekar HM. Computed tomographic evaluation of mediastinal masses. J Evol Med Dent Sci. 2015;4(57):9951-63.
7. Dixit R, Shah NS, Goyal M, Patil CB, Panjabi M, Gupta RC, et al. Diagnostic evaluation of mediastinal lesions: analysis of 144 cases. Lung India. 2017;34(4):341-8.
8. Hattiholi VV, Gupta P, Hattiholi J. Role of multidetector computed tomography in the evaluation of mediastinal mass lesions. Int J Anat Radiol Surg. 2018;7. [Issue and page numbers required].
9. Gadia P, Ukani BV, Singh S, Kotak A, Rathod YR. Evaluation of mediastinal mass lesions using computed tomography and correlation with histopathological diagnosis. Natl J Med Res. 2019;9(1). [Page numbers required].
10. Singh SS, Sachar S, Toppo JN, Acharya A. Computed tomographic evaluation of mediastinal mass lesions. Int J Contemp Med Surg Radiol. 2019;4:A94-8.

11. El Shalakany NM, Radwan SA, Taha AM, Dawoud MF. Multi slice computed tomography in assessment of posterior mediastinal lesions. J Adv Med Med Res. 2021;33(2):1-8.

12. Kumar M, Sharma T, Jain M, Raj P, Singh D, Talha M, et al. Computed tomographic evaluation of mediastinal masses: an experience at a tertiary care centre in Bareilly, India. J Evol Med Dent Sci. 2021;10(35):3017-24.

© The Author(s). 2026 Open Access. This article is distributed under the terms of the Creative Commons Attribution 4.0 International License (https://creativecommons.org/licenses/by-nc/4.0/), which permits unrestricted use, distribution, and non-commercial reproduction in any medium, provided you give appropriate credit to the original author(s) and the source, provide a link to the Creative Commons license, and indicate if changes were made. The Creative Commons Public Domain Dedication waiver (http://creativecommons.org/publicdomain/ zero/1.0/) applies to the data made available in this article, unless otherwise stated.